

HISTORICAL NOTES

THE HISTORY OF THE RECTAL CANCER SURGERY

**Georgiana Bianca Constantin^{1,2}, D. Firescu^{1,3}, D. Voicu^{1,4}, Cristina Șerban^{1,3}, R. Mihailov^{1,4},
Rodica Bîrlă², S. Constantinoiu²**

¹Faculty of Medicine and Pharmacy, “Dunărea de Jos” University, Galați

⁴The University of Medicine and Pharmacy Carol Davila, Bucharest

²Clinical Emergency County Hospital “Sf. Ap. Andrei” Galați

³Emergency County Hospital Brăila

Corresponding author: Georgiana Bianca Constantin

E-mail: constantin_bianca2009@yahoo.com

Abstract

In 1826, Lisfranc practiced a perineal circular incision, without opening the peritoneum. 50 years later, Verneuil and then Dolbeau and Denonvilliers practiced more extensive resections. In 1907, Lockart-Mummery described the operation that bears his name. In 1875, Kocher and Volkmann used the sacral approach that has been popularized by Kraske. Later, it became well known in the whole world and, with some little changes, it has been used in Europe by Bardenhaver, Hochenegg, Billroth, Rehn, Heinike and Rygidier and in the USA by Harrison Cripps, Edwards, Bevan and Grey Turner. Almost all of them resected the rectum and reestablished the continuity with a primary anastomosis. It seems that Volkmann practiced the combined abdominal and perineal approach for the first time in 1877, followed by Czerny and Köenning. Between 1896-1899, Quenu popularized this technique. In 1908, Ernest Miles began to use the technique and in 1914 he published the results. The resection of the posterior wall of the vagina in a rectum cancer has first been made by Hildebrant in 1879. The abdominal approach has been used by Hartmann in 1923. In 1930, Dixon together with Mayo, Waugh, Black and Judd described the “Mayo clinic operation”, meaning the resection of the rectal tumor with extraperitoneal anastomosis. They called that “anterior resection” and in 1948 they published their 20 years’ experience results and they definitely popularized the technique.

Keywords: *history, surgery, rectal cancer*

Introduction

The surgery of rectal cancer has had a continuous evolution, not only due to the technical discoveries in medicine, but also thanks to those surgeons who will remain in history as pioneers of this field.

Over time, the surgical treatment of the rectal cancer has been achieved using many ways of approach, some of them only having historical interest, but others are still in current use, with good results.

The open surgery in rectal cancer

The perineal approach

The first attempt to resect a rectal tumor through perineal approach has been made by Faget in 1739 [1].

In 1826, Lisfranc (Figure 1) has practiced a circular perineal incision, without opening the peritoneum, resecting the last 8 cm of the colon [2].



Figure 1 – Jacques Lisfranc de St. Martin (1790-1847)

50 years later, August Verneuil and then Dolbeau and Denonvilliers (Figure 2) have practiced larger resections, through a perineal incision posterior prolonged as a rocket, which allowed a larger operator field [3].



Figure 2 – Charles-Pierre Denonvilliers (1808-1872)

In 1884, Maurice Polloson has described a method to achieve a lavage through the distal end of an iliac anus and then to make the perineal resection [2].

In 1907, the English surgeon Lockart-Mummery (Figure 3) has described the operation that bears his name. His technique implied the making of a small laparotomy in the left iliac fossa, through which there could be done the exploration of the abdomen and a sigmoid colostomy, the procedure being completed after 2 weeks. This technique allowed the resection of tumors situated at least 25 cm from the anus [2].



Figure 3 – John Percy Lockhart-Mummery (1875-1957)

The sacral approach

In 1875, Kocher (Figure 4) and Volkmann have used this approach, that was later popularized by Kraske (Figure 5), who has detailed this technique in 1885 (Figure 6) at the German Congress of Surgery [2]. Later, the procedure became known in the entire world and it has been used in Europe (with small changes) by Bardenhaver, Hochenegg, Billroth (Figure 7), Rehn, Heinike and Rygidier, in the USA by Harrison Cripps (1907), Swinford Edwards (1908), Arthur Bevan and Grey Turner (1931) (Figure 8). Almost all of them have resected the rectum and restored the continuity through a primary anastomosis. Using this approach, Mandl reported in 1922 a survival of 30 % at 5 years and a mortality of 11,6 % [2].




Figure 4 – Emil Theodor Kocher (1841-1917)



Figure 5 – Paul Kraske (1851-1930)

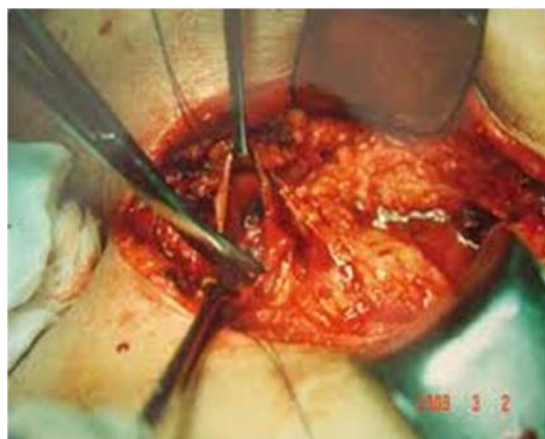


Figure 6 – Kraske's technique



Figure 7 – Theodor Billroth (1829-1894)

The end of the 19th century was marked by the discovery of the rectal fascia by Thoma Ionescu (Figure 9), the founder of the Romanian school of anatomy and surgery. He described this anatomical part in Poirier's treaty, published in Paris in 1894, 5 years before Waldeyer (Figure 10) mentioned the same structure [4].

This debate on the primacy on the description of the rectal fascia/ fascia propria recti was probably due to the fact that the cover of Paul Poirier's treaty, vol. IV, fasc. 1 (where we can find the name of the Romanian surgeon T. Jonnesco, as author of the digestive anatomy chapter) didn't contain the year of publication. The publishing of the volumes of this treaty has begun in 1892, but vol. IV has been published in 1894, according to most citations [4].




Figure 8 – George Grey Turner (1877-1951)



Figure 9 – Thoma Ionescu (1860-1926)

The combined approach abdominal and perineal

It seems that Volkmann (Figure 11) has practiced this double approach for the first time in 1877, followed by Vincent Czerny (1883) and Koenning (1888) [2].

Between 1896-1899, Quenu (Figure 12) has popularized the technique [2].

At the French Congress of Surgery in 1907, Gouilloud has published his personal statistics using this approach [5].




Figure 10 – Heinrich Wilhelm Gottfried von Waldeyer-Hartz (1836-1921)




Figure 11 – Richard von Volkmann (1830-1889)



Figure 12 – Edouard Quenu (1852-1933)

In 1908, Ernest Miles (Figure 13) has started using the technique and in 1914 he has published his results in 61 cases, reporting a mortality of 36,2 % [6]. Miles ligatured down the inferior mesenteric artery; instead, Moynihan considered that the surgery for cancers wasn't "the organ's surgery, but the lymph system anatomy" [7]. The answer to this issue is still a subject of controversy.




Figure 13 – William Ernest Miles (1869-1947)

In 1925, in Argentina, Bengolea has chosen this approach for a rectal tumor with adhesion to the uterus. He managed to obtain the healing by resecting the rectal tumor and also practicing a Wertheim operation [5].

The vaginal approach

The resection of the posterior wall of the vagina has been practiced for the first time in 1879 by Hildebrandt [2].

In Frankfurt, Rhen has described the operating times and the technique has been very well detailed in his student's thesis, Liermann [2].

The abdominal approach

Hartmann (Figure 14) has used this approach for the first time in 1923, in order to resect a rectal tumor without an anastomosis. Later, Rankin and Muir (1939) and Gabriel (1948) have reported very good results using the technique [1].




Figure 14 – Henri Albert Hartmann (1860-1952)

The first attempts to resect a rectal tumor through this approach with primary anastomosis belong to Rutheford Morrison and Balfour (1910), but it was Dixon (Figure 15) together with Mayo (Figure 16), Waugh, Black and Judd who described the „Mayo clinic operation" in

1930, consisting of the resection of the tumor with extraperitoneal anastomosis. They called this operation „anterior resection” and in 1948 they have reported the results of their 20 years’ experience. Dixon presented his work at the American Surgical Association meeting in Quebec and published it the same year in *Annals of Surgery* [2].




Figure 15 – Claude Dixon (1893-1968)

The Romanian surgeon Florian Mandache (Figure 17), whose surgical concerns have focused on the rectal surgery, has imagined an original technique, “rectosigmoid resection, intraanal intubation, preserving the anal mucosa and colo/ileo-anal/rectal anastomosis without suture”. He has published his work in *Chirurgia* (1954) and *La Presse Medicale* (1959) [4].



Figure 17 – Florian Mandache (1912-1989)




Figure 16 – William James Mayo (1861-1939)



Figure 18 – Mark Mitchell Ravitch (1910-1989)

In 1957, he has written an ample monograph, “The surgery of the rectum”, which is still a reference book.

In 1979, Ravitch (Figure 18) and Steichen (Figure 19) have described their technique to practice a mechanical anastomosis [8].



Figure 19 – Felicien Steichen (1926-2011)



Figure 20 – Richard Heald

Between 1980-1986, Parks, Lazorthes and Parc have practiced many types of colo-anal mechanical anastomosis, including for lower rectal tumors [1].

In 1982, the English surgeon Richard Heald (Figure 20) has described a resection technique based on the embryological development, consisting of the resection of the tumor and the mesorectum to the level of the levator ani muscle. He called this technique “total mesorectal excision” and it became gold standard in the western countries [9, 10].

The laparoscopic and robotic surgery in rectal cancer

In 1991, Jacobs et al. (in Miami, Florida) have published the first laparoscopic assisted colectomy [11]. In the USA, there have been published many randomized prospective studies, which revealed the non-inferiority of the laparoscopy compared to the open surgery. Other trials began in Spain, England and China. The eventual superiority of the laparoscopic interventions in rectal cancers is still a very debated subject [12, 13].

The using of the Da Vinci robot in digestive surgery has been approved by the FDA in the USA in 2000. The first description of a robotic operation in colorectal surgery has been made in 2001 and the first robotic total mesorectal excision has been practiced in 2006 [14].

The rectal cancer surgery will continue to be influenced by the technical medical innovations. Regardless of the approach, the standard for all interventions has to be the oncological radicality.

References

- [1] MM Lirici, C. Hüscher. Techniques and technology evolution of rectal cancer surgery: a history of more than a hundred years, *Minimally Invasive Therapy & Allied Technologies*, 2016, 25:5, 226-233
- [2] AM Minetti, JD Manoni- Historia de la cirugía del cancer colorectal. *Rev Argent Coloproct* ,2013 , VOL. 24, N° 3 : 107-110
- [3] MM Sevilla. Historia del cáncer del recto y su tratamiento quirúrgico. *Revista Mexicana de Coloproctología*. Vol. 11, No. 2. Mayo-Agosto 2005, pp 60-63

- [4] C. Vasilescu. Toma Ionescu sau Wilhelm von Waldeyer? Teaca rectului sau fascia propria recti? Istoria unei idei călătoare. Chirurgia nr 3, mai-iunie 2010, 105: 305-315
- J.M. Díaz-Pavón, R. Jiménez-Rodríguez, F. de la Portilla-de Juan. Cirugía robótica en el cáncer colorectal. Cirugía andaluza. Vol 29, nr 4, nov 2018, p 515-519
- [6] Miles WE. A method of performing abdomino-perineal excision for carcinoma of the rectum and of the terminal portion of the pelvic colon (1908). CA Cancer J Clin 1971;21:361-4
- [7] Moynihan BGA. The surgical treatment of cancer of the sigmoid flexure and rectum. Surg Gynecol Obstet 1908;6:463-8
- [8] Ravitch MM, Hirsch LC, Noiles D. A new instrument for simultaneous ligation and division of vessels, with a note on hemostasis by a gelatin sponge-staple combination. Surgery 1972;71:732-7
- [9] Heald RJ, Moran BJ, Ryall RD, Sexton R, MacFarlane JK. Rectal cancer: the Basingstoke experience of total mesorectal excision, 1978-1997. Arch Surg 1998;133:894-9
- [10] Heald RJ, Moran BJ, Ryall RDH, Sexton R, MacFarlane JK. Rectal Cancer: The Basingstoke Experience of Total Mesorectal Excision, 1978-1997. Arch Surg. 1998;133(8):894-898. doi:10.1001/archsurg.133.8.894
- [11] M. Jacobs, J. C. Verdeja, H. S. Goldstein, Minimally invasive colon resection (laparoscopic colectomy), Surgical Laparoscopy & Endoscopy, vol. 1, no. 3, pp. 144-150, 1991
- [12] J. Fleshman, D. J. Sargent, E. Green et al. Laparoscopic colectomy for cancer is not inferior to open surgery based on 5-year data from the COST Study Group trial, Annals of Surgery, vol. 246, no. 4, pp. 655-662, 2007
- [13] Bonjer HJ, Deijen CL, Abis GA, Cuesta MA, van der Pas MHGM, de Lange-de Klerk ESM. for the COLOR II Study Group., et al. A randomized trial of laparoscopic versus open surgery for rectal cancer. N Engl J Med 2015;372:1324-32
- [14] J.M. Díaz-Pavón, R. Jiménez-Rodríguez, F. de la Portilla-de Juan. Cirugía robótica en el cáncer colorectal. Cirugía andaluza. Vol 29, nr 4, nov 2018, p 515-519