

## CLINICAL CASE

**AN UNUSUAL CASE OF CEREBELLAR VENOUS ANGIOMA ASSOCIATED WITH TEMPORAL CAVERNOMA – PATHOPHYSIOLOGICAL, DIAGNOSTIC, AND SURGICAL CONSIDERATIONS**

**Tabita Larisa Cazac<sup>1</sup>, Ioana Andreea. Dărămuș<sup>1</sup>, B.C. Dumitrescu<sup>2</sup>, V. Ciubotaru<sup>2</sup>, Ligia Gabriela Tătăranu<sup>1,2</sup>**

<sup>1</sup>"Carol Davila" University of Medicine and Pharmacy, Bucharest, Romania

<sup>2</sup>"Bagdasar-Arseni" Emergency Clinical Hospital, Bucharest, Romania

Corresponding author: Tabita Larisa Cazac

Phone no. 0040766323590

E-mail: tabi\_cazac@yahoo.com

**Abstract**

*Cerebral vascular malformations are hamartomas, classified into four distinct groups: arteriovenous malformations, cavernous malformations, capillary telangiectasias, and developmental venous anomalies. These abnormal vascular entities have distinct histopathological, radiological, and clinical features, which make them different from one another. We report a case of a 37-year-old man, who presented with headaches, generalized grand mal seizures, and an episode of loss of consciousness, due to a left temporal cavernoma. Gadolinium-enhanced T1-weighted MR images showed a left temporal "popcorn-like" lesion, with heterogeneous enhancement, measuring 15/17/18 mm, suggestive of a cavernoma (angiographically occult malformation). The T2-weighted MRI showed a right cerebellar venous plexus, draining into a larger central vein and the angiogram revealed the pathognomonic caput medusae aspect of a venous angioma. Microsurgical resection of the left temporal cavernous malformation was performed using a left frontal temporal approach. The venous angioma was spared to avoid venous infarction and cerebral edema with devastating vital consequences. The intra- and postoperative courses were uneventful with total recovery. The seizures remitted under anticonvulsant therapy, and the postoperative computer tomography investigation were within normal limits. The venous angioma was situated in the right cerebellar hemisphere, rather than near the cavernoma, its location making this the particular aspect of this case.*

**Keywords:** cerebellar venous angioma, temporal cavernoma, anticonvulsant therapy

**Introduction**

We report an unusual case of a non-hemorrhagic left temporal cavernoma associated with a right cerebellar venous angioma in a 37-year-old patient.

The left temporal cavernous malformation was microsurgically resected, using a left frontal temporal approach. The right cerebellar venous angioma was left in situ.

The patient's medical records, imaging, treatment, and follow-up have been reviewed over a four-year period since surgery.

## Case presentation

A 37-year-old male presented at our Department of Neurosurgery four years ago, with grand mal convulsive seizures, diffuse headache and an episode of loss of consciousness, experienced one week previously. He experienced no other disturbance of consciousness, no cranial nerve abnormalities, and no sensory deficits or motor paresis.

On admission, the patient was neurologically intact except for the grand mal seizures, for which antiepileptic drugs were administered before surgery. No motor, focal or sensory deficits, except headaches, were detected, and there were no signs of intracranial hypertension. ECG and chest X-ray were within normal limits. The patient's vital signs were normal: blood pressure 130/80 mm Hg, heart rate 80 beats/min.

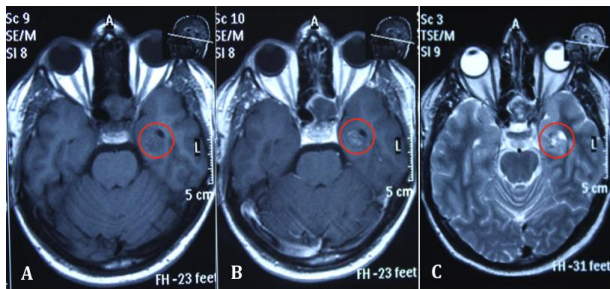


Figure 1 - Gadolinium-enhanced T1-weighted MR

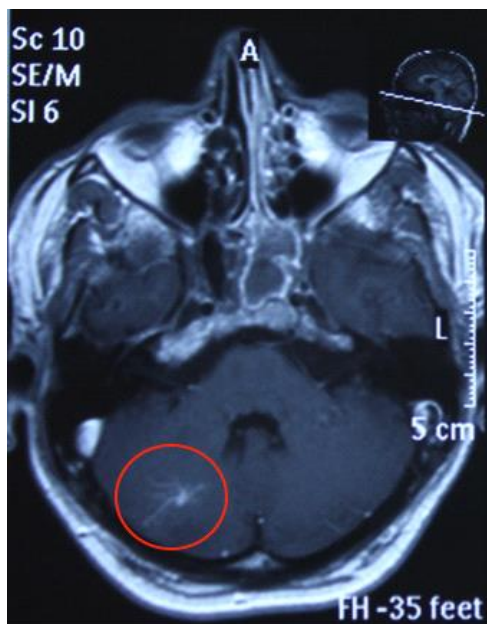


Figure 2 - T2-weighted MRI

Gadolinium-enhanced T1-weighted MR images (Figure 1) showed a left temporal mass with a reticulated core of mixed signal intensity, surrounded by a hypointense rim of hemosiderin. The appearance was similar to a “popcorn-like” lesion, with heterogeneous enhancement, measuring 15/17/18 mm, suggestive of a cavernous malformation. The T2-weighted MRI (Figure 2) showed a right cerebellar venous plexus draining into a larger central vein, and the angiogram (Figure 3) revealed the pathognomonic caput medusae or umbrella aspect of the venous malformation. As expected, there was no evidence of the left temporal mass on the angiography.

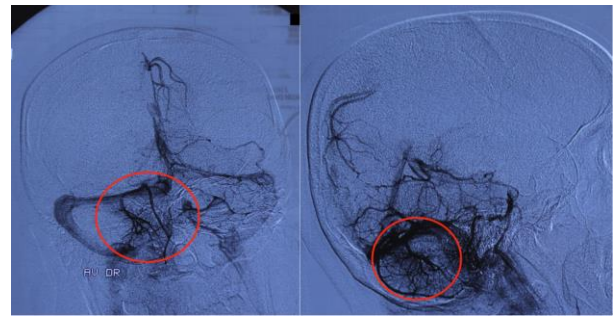


Figure 3 - Angiogram

The patient was diagnosed with a left temporal cavernoma and right cerebellar venous angioma based on the symptoms, clinical and laboratory investigations.

An elective surgical procedure was proposed, consisting of a total microsurgical resection of the left temporal cavernous malformation, using a left frontal temporal approach. The venous angioma was spared to avoid venous infarction and cerebral edema with devastating vital consequences.

Preoperatively, the patient received Dexamethasone 16 mg/d, Furosemide 40 mg/d, antiepileptic and analgesic drugs and intravenous hydration. The neurosurgical operation was performed a few days after admission to hospital.

Under general anesthesia, the patient was put in a supine position with the head rotated to 30 degrees and elevated 10 to 15 degrees.

A frontal-temporal skin incision was performed and the skin was dissected from the superficial temporal fascia and retracted. The superficial temporal fascia and muscle were opened in the same direction as the skin incision

and the bone was exposed after subperiosteal dissection.

A left frontal temporal craniotomy was performed and the resulting bone flap was centered over the depression of the sphenoid ridge. The lateral part of the sphenoid ridge was removed and a semilunar anterior-inferior dural flap was realized. The cavernous malformation was easily identified as a grey-reddish, solid, well-defined, hypervascularized mass, with a diameter of about 15/17/18 mm. The mass was shrunk with bipolar coagulation and its surrounding hemosiderin ring removed to prevent postoperative seizures.

Histological examination confirmed the diagnosis of a cavernous haemangioma. Adjacent parenchyma presents reactive astrocytosis with erythrocytes.

The postoperative course was uneventful with a total recovery. The patient was conscious after surgery. The seizures remitted under anticonvulsant therapy. No other cranial nerve abnormalities, motor paresis or sensory impairments were detected. He was discharged from hospital in good condition seven days after surgery.

The patient has been recalled every year for a neurosurgical consultation. The annual postoperative computer tomography investigations showed total surgical removal of the cavernous malformation. The venous angioma did not show any sign of bleeding and no other de novo cavernomas have been seen as at the present time (Figures 4,5).

At the most recent neurosurgical consultation, the patient showed no focal, motor, or sensory neurological deficits, no cranial nerve deficits, and no signs of intracranial hypertension. The CT scan images had a normal postoperative aspect.

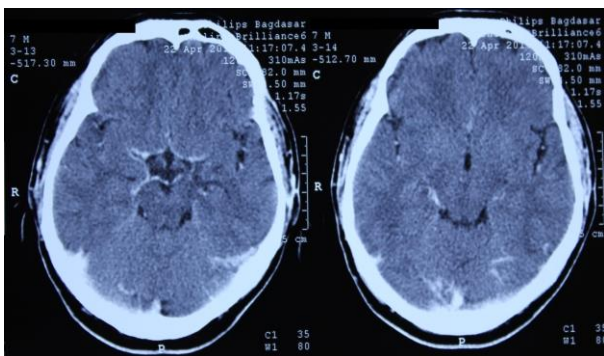


Figure 4 - Postoperative computer tomography

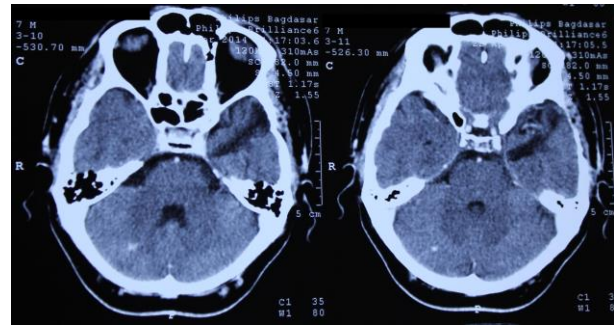


Figure 5 - Postoperative computer tomography

## Discussions

Cerebral vascular malformations are hamartomas [1, 2], classified by McCormick and colleagues into four distinct groups: arteriovenous malformations (AVMs), cavernous malformations (CMs), capillary telangiectasias, and developmental venous anomalies (DVAs) [1]. These abnormal vascular entities have distinct histopathological, radiological, and clinical features, which make them different from one another [3].

Cavernous malformations (cavernous hemangiomas, cavernous angiomas or cavernomas) are defined as well circumscribed, benign, vascular lesions. They consist of sinusoidal vascular channels with irregular, thick and thin walls, located within the brain, but with no intervening cerebral parenchyma, large feeding arteries or large draining veins [17].

Cavernomas are visualized on MRI as lesions with a reticulated center of mixed signal intensity surrounded by a hypointense margin of hemosiderin. They may appear as a "mulberry" or as "popcorn-like" masses, which show hemorrhage in different types of evolution: type I (subacute hemorrhage), type II (mixed subacute and chronic; the classic "popcorn-like" lesions), type III (chronic), and type IV (small hypointensity on gradient echo) [20]. Although they are vascular malformations, cavernomas are angiographically occult venous malformations.

Developmental venous anomalies (venous malformations, venous angiomas, medullary venous malformations, or caput medusae) are the most common intracranial vascular malformation (60% of all intracranial vascular lesions [16] and up to 2.5% of autopsy cases

[19]). A vascular angioma is composed of radially medullary veins, surrounded by normal brain tissue and converging in a central dilated trunk. There is no abnormal arteriovenous shunt, venous angioma draining the surrounding normal brain structures toward either the superficial system or, rarely, the deep venous system [16].

Venous malformations are best diagnosed on angiography, showing the pathognomonic caput medusae in the venous phase [23] or on T2 MRI, showing a venous plexus draining into a larger central vein, which exhibits high-velocity signal loss [27], with enhancement with gadolinium on T1 contrast MRI.

Reports have described mixed or transitional malformations with one or more histopathological characteristics within the same lesion: venous angiomas with cavernomas [4, 5, 6, 7, 8, 9, 10, 11], cavernomas with capillary telangiectasias [8, 12, 13], capillary telangiectasias with developmental venous anomalies, and venous angiomas with both cavernomas and capillary telangiectasia [2, 8]. The coexistence of a cavernous malformation and a venous angioma is the most common mixed vascular malformation [18].

In our reported case there is a distinct differentiation between the left temporal cavernous malformation and the right cerebellar venous angioma. The appearance of “popcorn-like” aspect of the left temporal cavernoma, with heterogeneous enhancement and mixed intensities and the pathognomonic caput medusae or umbrella aspect of the venous malformation can be observed on our imaging investigations.

In most series clinical signs and symptoms are attributed to cavernous malformations by direct compression or by hemorrhage [28]. The current view is that venous angiomas are benign congenital lesions, usually asymptomatic, resulting from failure of normal embryogenesis [21]. The association between a venous angioma and a cavernoma within the same lesion leads to a more aggressive clinical course [16].

The right venous angioma was asymptomatic, as reported in the literature, the grand mal seizures being a consequence of the hemosiderin surrounding the cavernoma, a major cerebral irritating factor.

The association of cavernomas and vascular angiomas within the same lesion has raised the question as to whether or not a cause-effect exists between these two entities. Many authors [5,6,11,16,17] have set out a number of arguments which favor the theory mentioned above: abnormal hemodynamics (hypertension) of venous malformations which might induce de novo formation of cavernomas [21, 22, 23], the high sensibility of venous angiomas which might cause microhemorrhage, leading to a reactive angiogenesis (also called “hemorrhagic angiogenic proliferation”) [23] and, finally, chronically increased intraluminal pressure which might lead to hypoxia and angiogenesis [24]. Dillon [25] maintained that elevated venous pressure within a hemorrhagic venous angioma with angiographic stenosis could cause de novo formation of cavernomas, confirming the hemorrhagic role of venous hypertension [25].

These reports suggest a common pathophysiological process; there is, however, insufficient data currently to support this theory.

The particular aspect of our reported case was represented by the location of the venous angioma, which was situated in the right cerebellar hemisphere, instead of being located near the cavernoma. That could mean many things: there is no relationship between the two vascular malformations and they are, therefore, separate entities (we did not find any connection that could link the two lesions), or there is a predisposition for multiple cavernomas and the right cerebellar venous angioma could lead to a cavernoma. We cannot affirm the hypothesis that a venous angioma, situated in the same location preceded the left temporal cavernoma. We choose to treat these vascular malformations as separate entities with no link between them.

As many reports have suggested [16, 17, 18, 20], hemorrhage is caused by cavernomas and not by the developmental venous anomalies. We chose, therefore, to microsurgically resect the symptomatic, left temporal cavernoma, which had an increased risk of hemorrhage. We spared the right cerebellar venous angioma, which drain normal brain tissue, to avoid venous infarction and cerebral edema with devastating vital consequences.

In patients with cavernous malformations associated with venous angiomas, it is indicated

that every surgical attempt should be made to spare the venous angioma to avoid the risk of venous infarction [4, 29, 30]. In 1999, Porter and coworkers [29], in their series of surgically resected brainstem cavernous malformations, reported one postoperative death caused by cerebellar hemorrhagic infarction related to surgical compromise of the associated venous angioma. Other reports have sustained the appearance of the nonhemorrhagic infarction after spontaneous thrombosis of venous angiomas, validating the theory that venous anomalies are essential for the drainage of normal parenchyma [31].

## Conclusions

Cerebral vascular malformations are hamartomas, classified into four distinct groups: arteriovenous malformations, cavernous malformations, capillary telangiectasias, and developmental venous anomalies.

These abnormal vascular entities have distinct histopathological, radiological, and clinical features, which make them different from one another.

The coexistence of a cavernoma and a venous angioma is the most common mixed vascular malformation.

These angiographically occult venous angiomas (cavernomas) can be resected without causing morbidity, whereas the removal of venous angioma (angiographically detected) is likely to lead to brain swelling and hemorrhagic infarction.

## References

- [1]McCormick WF: The pathology of vascular ("arteriovenous") malformations. *J Neurosurg* 24:807–816, 1966
- [2]Maraire JN, Awad IA. Intracranial cavernous malformations: lesion behavior and management strategies. *Neurosurgery* 1995;37:591–605
- [3]Awad IA, Spetzler RF, Hodak JA, Awad CA, Carey R. Incidental subcortical lesions identified on magnetic resonance imaging in the elderly. I. Correlation with age and cerebrovascular risk factors. *Stroke* 1986;17:1084–1089
- [4]Rigamonti D, Spetzler RF. The association of venous and cavernous malformations. Report of four cases and discussion of the pathophysiological, diagnostic, and therapeutic implications. *Acta Neurochir (Wien)* 1988;92:100–105
- [5]Cakirer S. De novo formation of a cavernous malformation of the brain in the presence of a developmental venous anomaly. *Clin Radiol* 2003;58:251–256
- [6]Wurm G, Schnizer M, Nussbaumer K, Wies W, Holl K. Recurrent cryptic vascular malformation associated with a developmental venous anomaly. *Br J Neurosurg* 2003;17:188–195
- [7]Comey CH, Kondziolka D, Yonas H. Regional parenchymal enhancement with mixed cavernous/venous malformations of the brain. Case report. *J Neurosurg* 1997;86:155–158
- [8]Clatterbuck RE, Elmaci I, Rigamonti D. The juxtaposition of a capillary telangiectasia, cavernous malformation, and developmental venous anomaly in the brainstem of a single patient: case report. *Neurosurgery* 2001;49:1246–1250
- [9]Sheehan J, Lunsford LD, Kondziolka D, Flickinger J. Development of a posterior fossa cavernous malformation associated with bilateral venous anomalies: case report. *J Neuroimaging* 2002;12:371–373
- [10]Wilms G, Bleus E, Demaerel P, et al. Simultaneous occurrence of developmental venous anomalies and cavernous angiomas. *AJNR Am J Neuroradiol* 1994;15:1247–1254, discussion 1255–1257
- [11]Maeder P, Gudinchet F, Meuli R, de Tribolet N. Development of a cavernous malformation of the brain. *AJNR Am J Neuroradiol* 1998;19: 1141–1143
- [12]Rigamonti D, Johnson PC, Spetzler RF, Hadley MN, Drayer BP. Cavernous malformations and capillary telangiectasia: a spectrum within a single pathological entity. *Neurosurgery* 1991;28:60–64
- [13]Roberson GH, Kase CS, Wolpow ER. Telangiectases and cavernous angiomas of the brainstem: "cryptic" vascular malformations. Report of a case. *Neuroradiology* 1974;8:83–89
- [14]McCormick PW, Spetzler RF, Johnson PC, Drayer BP. Cerebellar hemorrhage associated with capillary telangiectasia and venous angioma: a case report. *Surg Neurol* 1993;39:451–457
- [15]Van Roost D, Kristof R, Wolf HK, Keller E. Intracerebral capillary telangiectasia and venous malformation: a rare association. *Surg Neurol* 1997;48:175–183
- [16]Paolo Perrini, M.D., Giuseppe Lanzino, M.D. The association of venous developmental anomalies and cavernous malformations: pathophysiological, diagnostic, and surgical considerations *Neurosurg Focus* 21 (1):E5, 2006;1-4
- [17]Mark S. Greenberg. *Handbook of Neurosurgery*. 7th ed. New York: Thieme Medical Publishers; 2010;1098-1114

- [18]Töpper R, Jürgens E, Reul J, Thron A: Clinical significance of intracranial developmental venous anomalies. *J Neurol Neurosurg Psychiatry* 67:234–238, 1999
- [19]Sarwar M, McCormick WF: Intracerebral venous angioma. Case report and review. *Arch Neurol* 35:323–325, 1978
- [20]Zabramski JM, Wascher TM, Spetzler RF, et al. The natural history of familial cavernous malformations: results of an ongoing study. *J Neurosurg* 1994;80:422–432
- [21]Awad IA, Robinson JR Jr, Mohanty S, Estes ML: Mixed vascular malformations of the brain: clinical and pathogenetic considerations. *Neurosurgery* 33:179–188, 1993
- [22]Circillo SF, Dillon WP, Fink ME, Edwards MS: Progression of multiple cryptic vascular malformations associated with anomalous venous drainage. Case report. *J Neurosurg* 81:477–481, 1994
- [23]Rigamonti D, Spetzler RF, Medina M, Rigamonti K, Geckle DS, Pappas C: Cerebral venous malformations. *J Neurosurg* 73:560–564, 1990
- [24]Wilson CB: Cryptic vascular malformations. *Clin Neurosurg* 38:49–84, 1992
- [25]Dillon WP: Cryptic vascular malformations: controversies in terminology, diagnosis, pathophysiology, and treatment. *AJNR Am J Neuroradiol* 18:1839–1846, 1997
- [26]Abe M, Hagihara N, Tabuchi K, Uchino A, Miyasaka Y: Histologically classified venous angiomas of the brain: a controversy. *Neurol Med Chir (Tokyo)* 43:1–11, 2003
- [27]Rigamonti D, Spetzler RF, Drayer BP, et al. Appearance of venous malformations on magnetic resonance imaging. *J Neurosurg* 1988;69: 535–539
- [28]Wilms, E. Bleus, P. Demaerel, G. Marchal, C. Plets, J. Goffin, and A. L. Baert. Simultaneous Occurrence of Developmental Venous Anomalies and Cavernous Angiomas. *AJNR Am J Neuroradiol* 15: 1247-1254, Aug 1994
- [29]Porter RW, Detwiler PW, Spetzler RF, Lawton MT, Baskin JJ, Derksen PT, et al: Cavernous malformations of the brainstem: experience with 100 patients. *J Neurosurg* 90:50–58, 1999
- [30]Sasaki O, Tanaka R, Koike T, Koide A, Koizumi T, Ogawa H: Excision of cavernous angioma with preservation of coexisting venous angioma. Case report. *J Neurosurg* 75:461–464, 1991
- [31]Konan AV, Raymond J, Bourgoin P, Lesage J, Milot G, Roy D: Cerebellar infarct caused by spontaneous thrombosis of a developmental venous anomaly of the posterior fossa. *AJNR Am J Neuroradiol* 20:256–258, 1999