

THE PTERIONAL APPROACH IN A CASE OF PLANUM SPHENOIDALE MENINGIOMA

Tabita Larisa Cazac¹, D.C. Ciotarla¹, Ioana Andreea Dărămuș¹, B.C. Dumitrescu²

¹The University of Medicine and Pharmacy “Carol Davila”, Bucharest, Romania

²Clinic of Neurosurgery, Third Department of Neurosurgery, Emergency Clinical Hospital Bagdasar-Arseni, Bucharest

Corresponding author: Tabita Larisa Cazac

Phone no. 0040766323590

E-mail: tabi_cazac@yahoo.com

Abstract

Meningiomas represent almost 15 percent of primary brain tumors and are the most common non-glial primary brain tumor. Parasellar meningiomas represent 5–10 percent of all intracranial meningiomas. They may arise from the diaphragma sellae, tuberculum sellae, planum sphenoidale, medial lesser wing of sphenoid, anterior clinoid, clivus, and cavernous sinus (Smith 2005). Planum sphenoidale meningiomas are located anterior to and in proximity to the olfactory groove. For an optimal postoperative outcome planum, sphenoidale meningiomas must be diagnosed early, and the operative procedures performed promptly and with utmost care. Ideally, management is intended to preserve and improve vision and consists of total resection with no injury to the neighboring vital structures. We report the case of a 64-year-old woman who presented with progressive visual disturbance, impairment of visual acuity, visual field defects and diffuse headache. Gadolinium-enhanced T1-weighted MR images showed a well-defined, suprasellar solid mass, measuring 30/35/40 mm. The lesion was hyperintense on T1-weighted imaging with homogenous enhancement and a broad dural attachment to the planum sphenoidale. The planum sphenoidale meningioma was successfully resected using a left pterional approach. The intraoperative and postoperative courses were uneventful with a total recovery. Improvement of visual acuity was noted and the postoperative computer-tomography investigation showed total surgical removal with no residual tumor.

Keywords: *pterional approach, sphenoid ridge, optochiasmal syndrome, planum sphenoidale, parasellar region, meningioma*

Introduction

We report the case of a patient diagnosed with a planum sphenoidale meningioma, treated in our Department of Neurosurgery. The tumor was totally resected using a left pterional approach. The patient's medical records, imaging, treatment, and follow up have been reviewed over a five-year period since surgery.

Case presentation

A 64-year-old woman presented, 5 years ago, to our Department of Neurosurgery with symptoms of opto-chiasmal syndrome, including progressive visual disturbance, impairment of visual acuity and field defects in both eyes (more persistent on the left side), and diffuse headache. She experienced no

disturbance of consciousness, no other cranial nerve abnormalities and no motor paresis.

Examination: On admission, the patient was neurologically intact except for the optochiasmatic syndrome. No motor, focal or sensory deficits except headaches, no signs of intracranial hypertension were detected.

Paraclinical investigations: ECG and chest X-ray were within normal limits. The patient's vital signs were normal: blood pressure 120/80 mm Hg, heart rate 85 beats/min.

Ophthalmological examination: revealed a bilateral peripheral superior nasal scotoma along with a slight decrease in retinal sensitivity in both eyes (more persistent on the left side).

Gadolinium-enhanced T1-weighted MR images: showed a well-defined, suprasellar solid mass, measuring 30/35/40 mm. The lesion was hyperintense on T1-weighted imaging with homogenous enhancement and a broad dural attachment to the planum sphenoidale (Figure 1)

Diagnosis: based on the symptoms, clinical and laboratory investigations, the patient was diagnosed with a planum sphenoidale meningioma. An elective surgical procedure was proposed, consisting of a total surgical removal of the tumor using a left pterional approach.

Preoperatively, the patient received Dexamethasone 16 mg/d, Furosemide 40 mg/d, analgesics and intravenous hydration. The neurosurgical operation was performed a few days after admission to hospital.

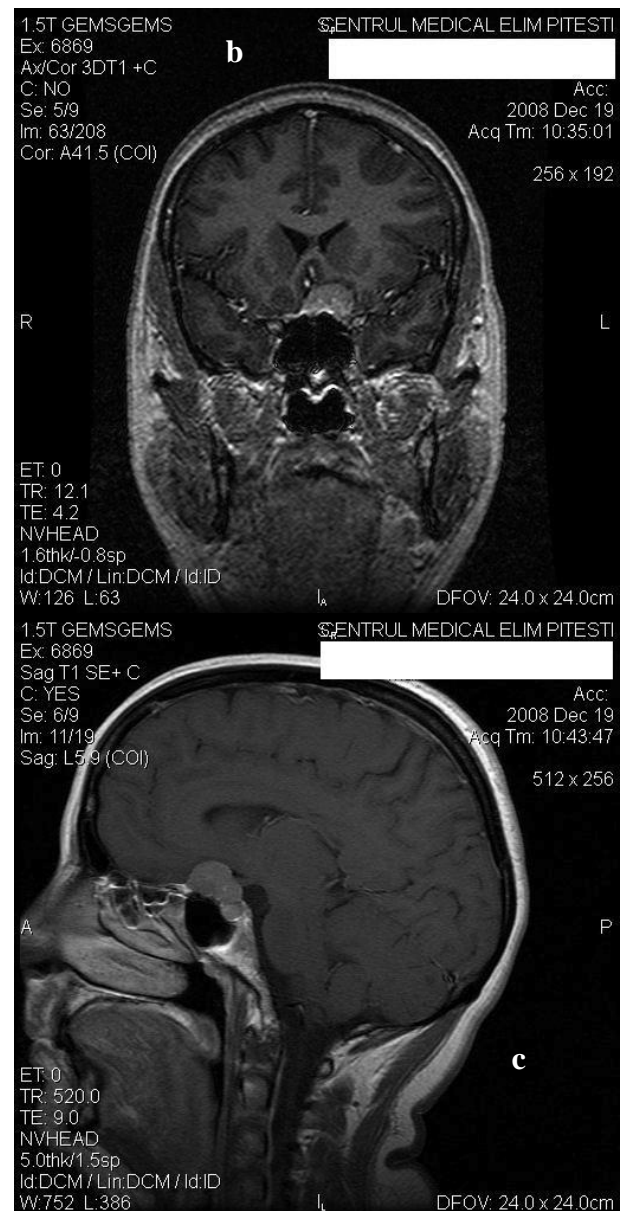
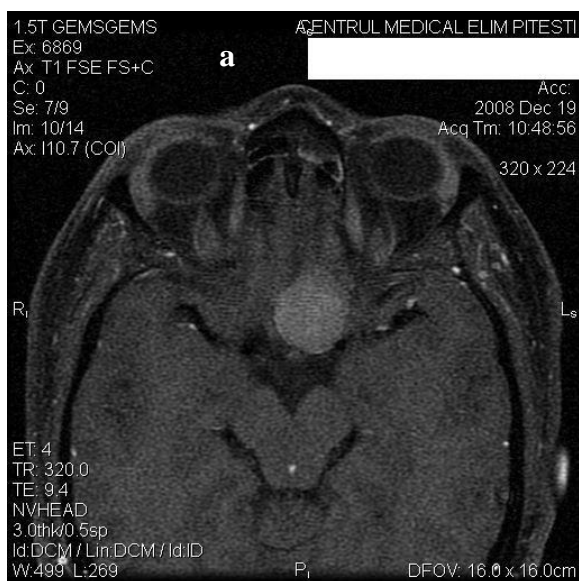


Figure 1 - Preoperative cerebral IRM: sagittal view (a), axial view (b), coronal view (c) reveal a well-defined, suprasellar solid mass, measuring 30/35/40 mm. The lesion is hyperintense on T1 weighted imaging with homogenous enhancement and a broad dural attachment to the planum sphenoidale. From the personal collection of Dr Bogdan C. Dumitrescu.

SURGICAL COURSE

Under general anesthesia, the patient was put in a supine position with the head rotated to 40 degrees and elevated 10 to 15 degrees to ensure that the final position of the head was above the level of the heart. The neck was maximally extended to increase the contribution of gravity and venous drainage. The head was placed in a Mayfield 3 pin head-holder.

A frontal-temporal skin incision was made behind the hairline from the zygomatic arch, one cm in front of the tragus (to avoid the frontal branch of the facial nerve and the frontal

branch of the superficial temporal artery), curving anteriorly and beyond the midline to add in skin retraction. The bleeding points were cauterized with a bipolar coagulator to avoid a bulky skin flap. The skin was dissected from the superficial temporal fascia and retracted with silk stitches. The superficial temporal fascia and muscle were opened in the same direction as the skin incision. The bone was exposed after subperiosteal dissection, and the hooks were repositioned to include the skin and muscular layers.

A left pterional craniotomy was performed. The main burr holes were made at the posterior insertion of the zygomatic arch and at the insertion of the zygomatic bone (near the frontozygomatic suture), the superior temporal line and supraorbital ridge. The resulting bone flap was centered over the depression of the sphenoid ridge. The lateral part of the sphenoid ridge was removed. A semilunar dural flap was performed, providing a 2 mm margin from the craniotomy to facilitate the dural closure. The dural flap was retracted anterior-inferior and secured with sutures. The tumor was easily identified as a gray-yellow, solid, relatively homogeneous, well-defined, polinodular, hypervascularized mass, with dimensions of about 30/35/40 mm – probably meningioma. The tumor was adherent to the planum sphenoidale. A peritumoral plane of dissection was developed and the tumor was piecemeal ablated with coagulation of its planum sphenoidale adhesions.

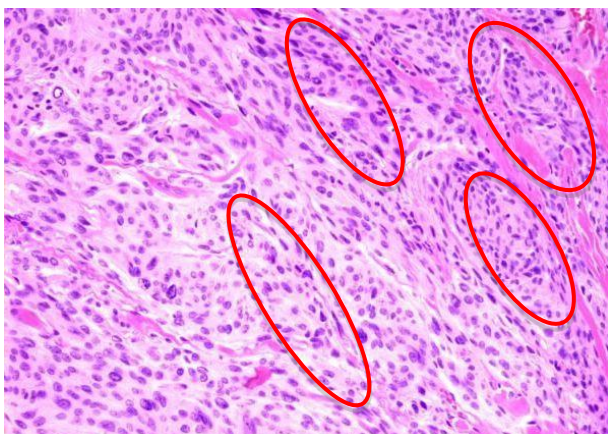


Figure 2 - Histological examination showing meningothelial cells with syncytial pattern with no mitoses or necrosis, confirming the diagnosis of meningothelial meningioma

Histological examination confirmed the diagnosis of meningothelial meningioma (Figure 2).

The intraoperative procedure was successful, with no complications.

POSTOPERATIVE COURSE

The postoperative course was uneventful with a total recovery. After surgery, the patient was conscious and slight improvement on her visual acuity was observed. No other cranial nerve abnormalities, motor paresis or sensory impairments were detected. She was discharged from hospital seven days after surgery in good condition.

The patient has been recalled every year for a neurosurgical consult. The annual postoperative computer tomography investigations showed total surgical removal with no residual or recurrent tumor (Figure 3,4,5,6).

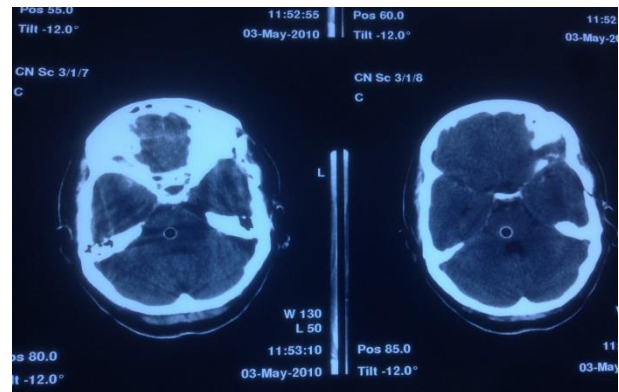


Figure 3 - Postoperative cerebral CT scan in 2010 showing total surgical removal with no residual or recurrent tumor. From the personal collection of Dr Bogdan C. Dumitrescu

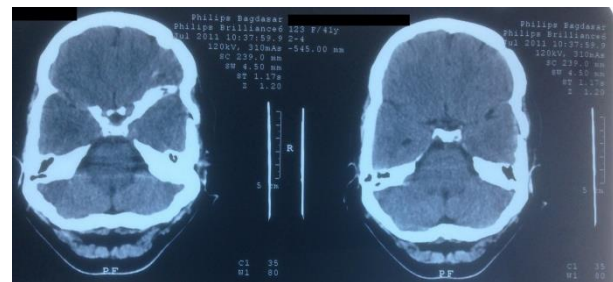

Figure 4 - Postoperative cerebral CT scan in 2011 showing total surgical removal with no residual or recurrent tumor. From the personal collection of Dr Bogdan C. Dumitrescu

On this year follow-up neurosurgical visit, the patient the patient has shown no focal, motor, or sensory neurological deficits, no cranial nerve deficits, and no signs of intracranial hypertension. No optochiasmatic syndrome has been observed. The CT scan images have revealed no signs of tumor recurrence or residual tumor.

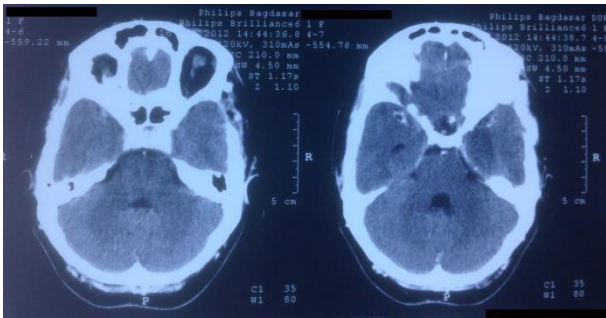


Figure 5 - Postoperative cerebral CT scan in 2012 showing total surgical removal with no residual or recurrent tumor. From the personal collection of Dr Bogdan C. Dumitrescu

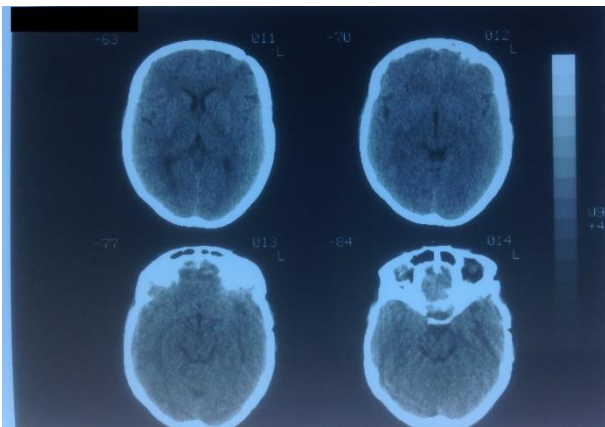


Figure 6 - Postoperative cerebral CT scan in 2014 showing total surgical removal with no residual or recurrent tumor. From the personal collection of Dr Bogdan C. Dumitrescu

Ophthalmological examinations have revealed persistent bilateral peripheral superior nasal scotoma along with a slight decrease in retinal sensitivity, but increase of visual acuity in both eyes. The optic fundus assessment was normal, showing an optic disc with clear and well-defined borders, retina and vessels with no pathological modifications.(Figure 7)

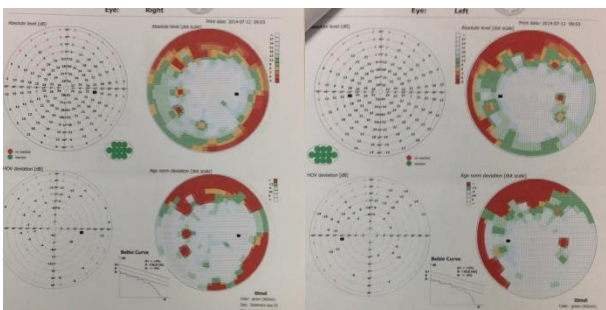


Figure 7. Visual field perimetry 5 years after surgery revealed persistent bilateral peripheral superior nasal scotoma along with slight decrease in retinal sensitivity, but increase of visual acuity in both eyes. From the personal collection of Dr. Bogdan C. Dumitrescu

Discussions

The sellar and parasellar region represent a complex anatomical area where a number of neoplastic, inflammatory, infectious and vascular diseases can develop. Although most sellar lesions are due to pituitary adenomas [1], a number of other pathologies involving the parasellar region may present in a similar manner. They arise from the normal pituitary elements (such as craniopharyngiomas, pituitary carcinomas, astrocytomas, and granular cell tumors) or may be of nonpituitary origin (such as meningiomas, germ cell tumors, and lymphoma) or may be metastases [2,3].

Meningiomas are the most common non-glial primary intracranial tumor in the adult population, comprising 30 percent of all primary brain tumors, with a peak incidence in adults aged between 40–70 years. They are slow-growing extra-axial brain neoplasms that arise from the arachnoid cap cells. Most meningiomas are considered histologically benign (over 90 percent) [4].

Meningiomas involving the parasellar region originate from the planum or jugum sphenoidale, tuberculum sellae, anterior clinoid processes, cavernous sinus or diaphragma sellae. They account for about 5–10 percent [5] of all intracranial meningiomas based on a review of the world literature (Cushing and Eisenhardt 1938, Ehlers and Malmros 1973, Fusek and Kunc 1969, Guillaumat 1937, Olivecrona 1967, Zülch 1956).

Tuberculum sellae meningiomas lie in a suprasellar subchiasmatic midline position, while planum sphenoidale meningiomas are located anterior to and in proximity to the olfactory groove. Meningiomas located in the planum sphenoidale region arise from the flat part of the sphenoid bone, anterior to the chiasmatic sulcus in the posterior part of the anterior cranial fossa [6].

For a correct diagnosis and management of planum sphenoidale meningiomas, a multidisciplinary approach is involved. Detailed endocrinological, ophthalmological, neuroimaging, neurological, histological studies and surgery-related features are required in order to distinguish them from other anterior skull base tumors.

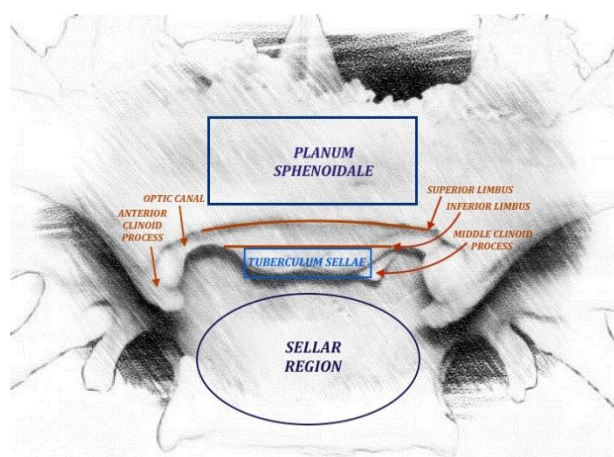


Figure 8 - Sellar and parasellar region anatomy. From the collection of Tabita Larisa Cazac

Planum sphenoidale meningiomas are closely bound with the optic nerves and optic chiasm, pituitary gland, cavernous sinus (which contains the cavernous part of the internal carotid arteries), oculomotor, trochlear nerves and the ophthalmic branch of the trigeminal nerve. Because of the anatomical relationship of these meningiomas to the optic nerves, there is a classic clinical presentation represented by the opto-chiasmatal syndrome, a primary optic atrophy with bitemporal hemianopia. Approximately two-thirds of patients complain of visual failure in one eye as the first symptom, and blindness in one eye may be present in half of the patients before surgery. Most patients show a slow progressive visual deterioration, and prompt treatment is intended to preserve and improve vision (Figure 8).

Imaging investigation of meningiomas are frequently characteristic and permit to distinguish them from other parasellar tumors [7]. Computer-tomography (CT) scans of meningiomas show hyperdense lesions with well-defined margins, homogenous enhancing, arising from the dura with an extensive attachment. On MR imaging, meningiomas are typically isointense on T1 and T2, enhancing homogeneously, with occasional areas of diffuse calcification, with a broad dural attachment.

Ideally, management consists of gross-total resection without injury to neighboring vital structures. Various approaches to the planum sphenoidale region are being used for resection and a variety of craniotomies (pterional, unilateral subfrontal, bilateral subfrontal) can be performed to achieve the most direct route to

this region with the fewest potential complications or anatomical limitations. Recently, there has been increasing interest in endoscopic transsphenoidal approaches, which are less invasive compared to the transcranial approach, and have demonstrated very good results so far, but require a well-trained surgical team [8].

For our particular case, the pterional approach was selected on the left side, where it was the most prominent visual deficit. This approach offered an extensive view of the optic nerves and chiasm and internal carotid artery, avoiding damage to the olfactory nerves. Other advantages were less retraction of brain tissue and a direct and shorter route to the planum sphenoidale region. The disadvantages of the pterional approach were narrow space and angle, and risk of profuse bleeding when removing the tumor.

The most important goal is vision preservation, which can be achieved by adhering to arachnoid planes around the optic nerves, chiasm, and brain tissue, as well as recognizing the optic apparatus vascular supply via perforating branches from the posterior ethmoidal, superior hypophysial, and anterior cerebral arteries. Careful step-by-step procedures are essential to treat planum sphenoidale meningioma in a quite complicated case such as ours.

Studies have shown that early decompression surgery presented visual improvement, while late decompression surgery presented constant visual deficit.

Conclusions

Planum sphenoidale meningiomas must be diagnosed early for a good postoperative outcome, and the operative procedures must be performed promptly and with utmost care, especially in patients presenting with symptoms of optic chiasm compression. Ideally, management is intended to preserve and improve vision and consists of total resection with no injury to the neighboring vital structures. Several surgical approaches to these tumors are possible; for the case we report we believe that the pterional approach yields minimal morbidity and allows the surgeon the greatest

intraoperative flexibility for dissection and tumor removal.

References

- [1]de Divitiis, Enrico; Cavallo, Luigi M: Extended Endoscopic Transsphenoidal Approach for Tuberculum Sellae Meningiomas, *Neurosurgery* 62 (6): 1192-1201, 2008.
- [2]Al-Mefty O, Holoubi A, Rifai A, Fox JL: Microsurgical removal of suprasellar meningiomas. *Neurosurgery* 16:364-372, 1985.
- [3]Arai H, Sato K, Okuda, Miyajima M, Hishii M, Nakanishi H, Ishii H: Transcranial transsphenoidal approach for tuberculum sellae meningiomas. *Acta Neurochir (Wien)* 142:751-757, 2000.
- [4]Fahlbusch R, Schott W: Pterional surgery of meningiomas of the tuberculum sellae and planum sphenoidale: surgical results with special consideration of ophthalmological and endocrinological outcomes. *J Neurosurg.* 2002 Feb;96(2):235-43.
- [5]Goel, Atul M.Ch: Tuberculum Sellae Meningioma: A Report on Management on the Basis of a Surgical Experience with 70 Patients. *Neurosurgery* 51: 1358- 1364, 2002.
- [6]allo G I, MD, Benjamin V, M.D.: Tuberculum sellae meningiomas: microsurgical anatomy and surgical technique, *Neurosurgery* vol 51, 2002.
- [7]Kitano M, Taneda M, Nakao Y. Postoperative improvement in visual function in patients with tuberculum sellae meningiomas: results of the extended transsphenoidal and transcranial approaches. *J Neurosurg.* 2007;107(2):337-346.
- [8]Mathiesen T, Kihlstrom L. Visual outcome of tuberculum sellae meningiomas after extradural optic nerve decompression. *Neurosurgery.* 2006;59(3):570- 576.
- [9]Pamir MN, Ozduman K, Belirgen M, Kilic T, Ozek MM. Outcome determinates of pterional surgery for tuberculum sellae meningiomas. *Acta Neurochir (Wien).* 2005;147(11):1121-1130