

REVIEW

## D3 LYMPHADENECTOMY FOR RIGHT- SIDED COLON CANCER– A MINI-REVIEW

I. Negoï<sup>1,2</sup>, Alina Prodan<sup>2</sup>, S. Marinescu<sup>3</sup>, Mihaela Vartic<sup>2</sup>, M. Beuran<sup>1,2</sup>

<sup>1</sup>”Carol Davila” University of Medicine and Pharmacy

<sup>2</sup>The Emergency Hospital of Bucharest, Romania

<sup>3</sup>Prof. Dr. Al. Trestioreanu Institute of Oncology, Bucharest, Romania

Corresponding author: Ionuț Negoï

Phone no. 0040215992308

E-mail: negoiiionut@gmail.com.

### Abstract

*The objective of this review of the literature is to detail the technical challenges associated with D3 lymphadenectomy for right-sided colon cancer, and to examine the terms used throughout the medical literature to describe the central lymph nodes. We conducted a review of the relevant English language literature, using the electronic search of the PubMed/Medline and Google Scholar databases. The medical literature does not indicate a clear limit between the D3 and D2 lymph nodes for right colon cancer. The central lymph nodes are defined as those located within one centimeter from the origin of the colic arteries. The D3 lymphadenectomy includes ligation of the right colon feeding arteries at their emergence from the superior mesenteric artery (SMA), thus allowing appropriate dissection of the central lymph nodes. The lymphadenectomy of the central lymph nodes requires dissection posterior to the superior mesenteric vein (SMV) when colic arteries have a posterior trajectory to this anatomical structure. An oncological resection for the right-sided colon cancer, with transection of feeding vessels at their emergence from the SMA, is technically demanding, especially when ileocolic and right colic arteries have a trajectory posterior to the SMV.*

**Keywords:** *thyroidectomy, papillary thyroid cancer, chronic thyroiditis, thyroid nodules*

### Introduction

Colorectal cancer varies over ten-fold around the world, the highest incidence being in Australia, Europe and North America [1]. According to the GLOBOCAN, the one-year prevalence of colorectal cancer in Romania in 2012 was 7278, being the second most frequent, after breast cancer (Figure 1).

The surgical resection represents the most important therapeutic approach for colon cancer, the oncological outcomes being improved by refinements of the dissection techniques, such as the complete mesocolic excision with central

vascular ligation or D3 lymphadenectomy [3]. Complete mesocolic excision (CME) with central vascular ligation (CVL) represents the European concept of extended lymphadenectomy for colon cancer, being proposed and standardized by Hohenberger et al. [4]. The D3 lymphadenectomy proposed by Eastern countries as Japan, Korea, and China is based on the same principle, which includes ligation of the ileocolic, right colic and middle colic arteries at their emergence from superior mesenteric artery [5].

The objective of this review of the literature is to detail the technical challenges

associated with D3 lymphadenectomy for right-sided colon cancer, and to examine the terms used throughout the medical literature to describe the central lymph nodes.

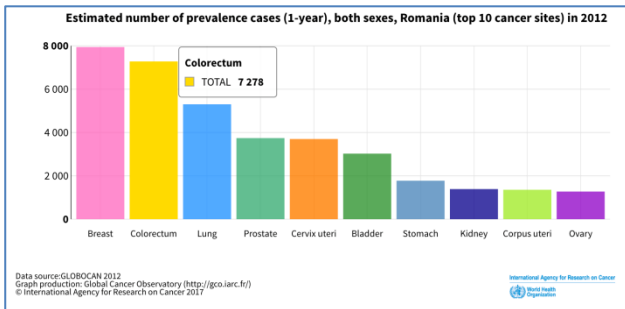


Figure 1 - The one-year prevalence of colorectal cancer in Romania in 2012 [2].

Materials and methods

We conducted a review of the relevant English language literature, using electronic search of the PubMed/Medline and Google Scholar databases. We have used the following search strategy: (((((colon) AND cancer[Title/Abstract])) AND right) AND ((lymphnode) OR lymph node)) AND (((main[Title/Abstract])ORcentral[Title/Abstract]) OR principal[Title/Abstract]).

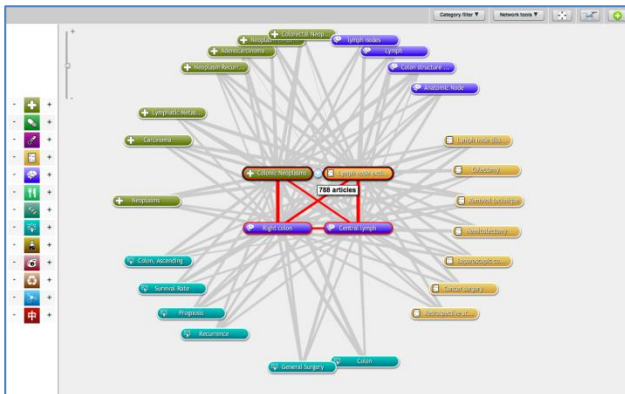


Figure 2: The Venn Diagram for the used search strategy [6].

Results

We have included 37 articles in the current review of the literature. The medical literature does not indicate a clear limit between the D3 and D2 lymph nodes for right colon cancer. The extent of lymphadenectomy for

right colon cancer is not clearly defined either by the National Comprehensive Cancer Network, or by the European Society of Medical Oncology guidelines [8]. A randomized control trial comparing D2 lymphadenectomy with complete mesocolic excision (RELARC trial) started to recruit patients in January 2016 [9].

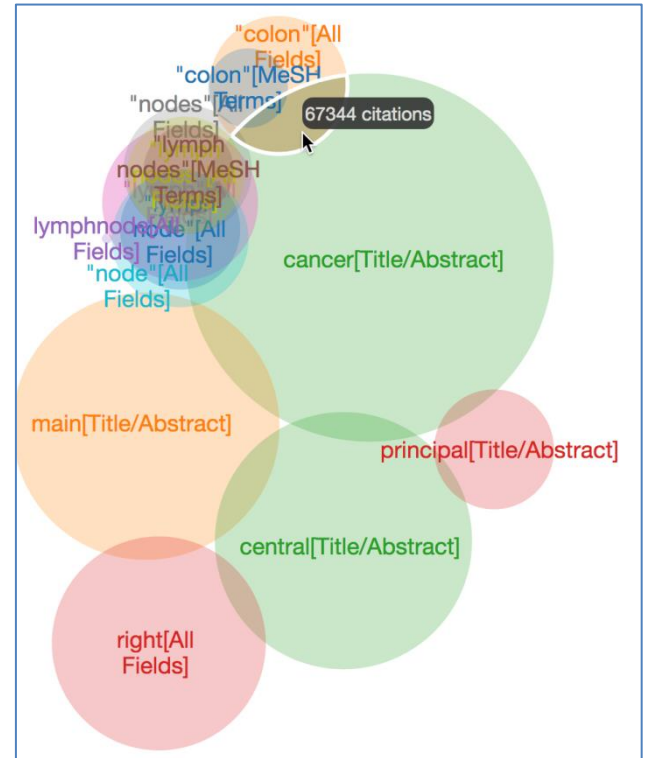


Figure 3: The biomedical map for the following search strategy: 'Colonic Neoplasms' (disease) (50270 connections)'Lymph node excision' (procedure) (16506 connections)'Right colon' (anatomy) (6550 connections)'Central lymph' (anatomy) (2019 connections) [7].

The central lymph nodes are defined as those located within one centimeter from the origin of the colic arteries. A systematic review including 47 articles, published in 2016 by Bertelsen et al. found a risk of metastases in central lymph nodes for right-sided tumors varying between 1 – 22% [10].

The D3 lymphadenectomy includes ligation of the right colon feeding arteries at their emergence from the superior mesenteric artery (SMA), thus allowing appropriate dissection of the central lymph nodes. The lymphadenectomy of the central lymph nodes requires dissection posterior to the superior

mesenteric vein when colic arteries have a posterior trajectory to this anatomical structure. Spasojevic et al. published the results of a postmortem study regarding the lymph node distribution in the D3 area of the right mesocolon [11]. In this study, the posterior ileocolic compartment (tissue located between the SMV – SMV – Toldt's fascia) contained a median of three lymph nodes (range one to five) when ileocolic artery crosses posterior to the SMV [11].

A Danish study compared 529 patients with complete mesocolic excision (CME) with 1701 patients with conventional surgery and it revealed a significantly higher rate of SMV lesions in the CME group (1.7% versus 0.2%,  $P < 0.001$ ) [12]. On the other hand, the CME was associated with a significant better four-year DFS, irrespective of UICC stage (CME versus non-CME – 85.8% versus 73.4%,  $P = 0.0014$ ) [13].

The latest guidelines published by the Japanese Society for Cancer of the Colon and Rectum (JSCCR) was published in 2014 [14]. According to this guideline, the D3 dissection is indicated in all cases of proven or suspected metastatic lymph nodes. In cases with negative lymph nodes on preoperative imaging and intraoperative exploration, the D3 lymphadenectomy may be performed for tumors invading muscularis propria (T2), these being associated with a rate of 1% of metastasis into the main lymph nodes [14]. An analysis of 46,304 patients from 96 hospitals from Japan, revealed changes in colorectal cancer care in Japan after guideline publication [15]; the D3 lymphadenectomy was performed in 58.4% versus 75% of patients with resection in 2001 versus 2010 [15].

Kanemitsu et al. published 370 consecutive patients with D3 lymph node dissection and no-touch isolation technique for right-sided colon cancer [16]. The five-year disease free survival (DFS) was 85% for stage III disease. 3% and 13.2% of patients had metastasis into the central and intermediate lymph nodes, with a five-year DFS of 36.4% and 83.5%, respectively [16].

## Conclusion

An oncological resection for the right-sided colon cancer, with transection of feeding vessels at their emergence from the SMA is technically demanding, especially when ileocolic and right colic arteries have a trajectory posterior to the SMV.

## References

- [1] Torre LA, Bray F, Siegel RL, Ferlay J, Lortet-Tieulent J, Jemal A. Global cancer statistics, 2012. *CA: a cancer journal for clinicians*. 2015;65(2):87-108. doi: 10.3322/caac.21262
- [2] Organization IAfRoC-WH. Cancer Today 2017 [cited 2017 13th of February]. Available from: [http://gco.iarc.fr/today/onlineanalysismultibars?mode=cancer&mode\\_population=continents&population=642&sex=0&cancer=6&type=2&statistic=0&prevalence=1&color\\_palette=default](http://gco.iarc.fr/today/onlineanalysismultibars?mode=cancer&mode_population=continents&population=642&sex=0&cancer=6&type=2&statistic=0&prevalence=1&color_palette=default).
- [3] Bertelsen CA. Complete mesocolic excision an assessment of feasibility and outcome. *Danish medical journal*. 2017;64(2).
- [4] Hohenberger W, Weber K, Matzel K, Papadopoulos T, Merkel S. Standardized surgery for colonic cancer: complete mesocolic excision and central ligation--technical notes and outcome. *Colorectal disease : the official journal of the Association of Coloproctology of Great Britain and Ireland*. 2009;11(4):354-64; discussion 64-5. doi: 10.1111/j.1463-1318.2008.01735.x
- [5] West NP, Kobayashi H, Takahashi K, Perrakis A, Weber K, Hohenberger W, et al. Understanding optimal colonic cancer surgery: comparison of Japanese D3 resection and European complete mesocolic excision with central vascular ligation. *Journal of clinical oncology : official journal of the American Society of Clinical Oncology*. 2012;30(15):1763-9. doi: 10.1200/jco.2011.38.3992
- [6] Sperr E. Available at: <https://pubvonn.appspot.com/> 2017 [cited 2017 13th of February].
- [7] Available at: <https://www.coremine.com/medical/-search> 2017 [cited 2017 13th of February].
- [8] Sondenaa K, Quirke P, Hohenberger W, Sugihara K, Kobayashi H, Kessler H, et al. The rationale behind complete mesocolic excision (CME) and a central vascular ligation for colon cancer in open and laparoscopic surgery : proceedings of a consensus conference. *International journal of colorectal disease*. 2014;29(4):419-28. doi: 10.1007/s00384-013-1818-2
- [9] Lu J-Y, Xu L, Xue H-D, Zhou W-X, Xu T, Qiu H-Z, et al. The Radical Extent of lymphadenectomy

- D2 dissection versus complete mesocolic excision of Laparoscopic Right Colectomy for right-sided colon cancer (RELARC) trial: study protocol for a randomized controlled trial. *Trials*. 2016;17:582. doi: 10.1186/s13063-016-1710-9
- [10] Bertelsen CA, Kirkegaard-Klitbo A, Nielsen M, Leotta SM, Daisuke F, Gogenur I. Pattern of Colon Cancer Lymph Node Metastases in Patients Undergoing Central Mesocolic Lymph Node Excision: A Systematic Review. *Diseases of the colon and rectum*. 2016;59(12):1209-21. doi: 10.1097/dcr.0000000000000658
- [11] Spasojevic M, Stimec BV, Dyrbekk AP, Tepavcevic Z, Edwin B, Bakka A, et al. Lymph node distribution in the d3 area of the right mesocolon: implications for an anatomically correct cancer resection. A postmortem study. *Diseases of the colon and rectum*. 2013;56(12):1381-7. doi: 10.1097/01.dcr.0000436279.18577.d3
- [12] Bertelsen CA, Neuenschwander AU, Jansen JE, Kirkegaard-Klitbo A, Tenma JR, Wilhelmsen M, et al. Short-term outcomes after complete mesocolic excision compared with 'conventional' colonic cancer surgery. *The British journal of surgery*. 2016;103(5):581-9. doi: 10.1002/bjs.10083
- [13] Bertelsen CA, Neuenschwander AU, Jansen JE, Wilhelmsen M, Kirkegaard-Klitbo A, Tenma JR, et al. Disease-free survival after complete mesocolic excision compared with conventional colon cancer surgery: a retrospective, population-based study. *The Lancet Oncology*. 2015;16(2):161-8. doi: 10.1016/s1470-2045(14)71168-4
- [14] Watanabe T, Itabashi M, Shimada Y, Tanaka S, Ito Y, Ajioka Y, et al. Japanese Society for Cancer of the Colon and Rectum (JSCCR) Guidelines 2014 for treatment of colorectal cancer. *International Journal of Clinical Oncology*. 2015;20(2):207-39. doi: 10.1007/s10147-015-0801-z
- [15] Ishiguro M, Higashi T, Watanabe T, Sugihara K. Changes in colorectal cancer care in japan before and after guideline publication: a nationwide survey about D3 lymph node dissection and adjuvant chemotherapy. *Journal of the American College of Surgeons*. 2014;218(5):969-77.e1. doi: 10.1016/j.jamcollsurg.2013.12.046
- [16] Kanemitsu Y, Komori K, Kimura K, Kato T. D3 Lymph Node Dissection in Right Hemicolectomy with a No-touch Isolation Technique in Patients With Colon Cancer. *Diseases of the colon and rectum*. 2013;56(7):815-24. doi: 10.1097/DCR.0b013e3182919093