

HYBRID APPROACH IN THE CASE OF A TYPE B COMPLICATED AORTIC DISSECTION

Lavinia Iftene¹, H. Moldovan²

¹”Carol Davila” University of Medicine and Pharmacy, Bucharest, Romania

²1st Department of Cardiovascular Surgery, “C.C.Iliescu” Institute of Cardiovascular Diseases

Corresponding author: Lavinia Iftene

Phone no. 040755299988

E-mail: iftene_lavinia@yahoo.com

Abstract

Thoracoabdominal aortic pathologies remain an intimidating surgical challenge for the field of cardiovascular expertise, having conventional open repair associated with significant rates of mortality and morbidity. Studies conducted by Dake Michael and Nienabar Christoph have reported the use of thoracic "stent-grafts" in patients who were believed to be at excessive risk for open surgery, pioneering an alternative procedure known as Thoracic EndoVascular Aortic Repair (TEVAR). Nowadays a significant number of patients with thoracoabdominal aortic aneurysms are unsuitable for TEVAR owing to the absence of graft seal zones. In such situations we rely on the "Hybrid" technique which allows the creation of proximal and distal landing areas in order to expand the appliance of the endovascular repair. Throughout this article we present the appliance of TEVAR in the case of a 48-year-old male, reported smoker, revealing a history of untreated hypertension and exertion angina, describing symptoms such as antero-posterior thoracic pain for the last hour before admission. CT scans guided us to the complete diagnostic of Stanford Type B Acute Aortic Dissection emerging from the origin of the left subclavian artery to the celiac trunk, right Suprarenalian Tumor and left pleural effusion. The HEART Team's decision was to institute strict preoperative antihypertensive treatment followed by hybrid debranching and TEVAR. The acknowledgement of a complete patient history (in our case the recognizing of pheochromocytoma and extensive coronary disease) is critical to the institution of optimal decisions regarding the management of patient's follow-up, especially when such devices still have significant limitations and shortcomings to promote wide application to all patients and pathologies.

Keywords: *hybrid approach, aortic dissection, complicated 2B*

Introduction

Thoracoabdominal aortic pathologies remain an intimidating surgical challenge for the field of cardiovascular expertise, having conventional open repair associated with significant rates of mortality and morbidity. Historically, the therapeutic options for treatment of thoracoabdominal and descending

thoracic aortic pathologies ranged from a very conservative medical management to an extremely invasive open surgical repair in situations such as impending rupture and organ malperfusion due to aortic branch vessel compromise[1,2] (Figure 1).

Studies conducted by Dake Michael et al and Nienabar Christoph et al have reported the use of thoracic "stent-grafts" in patients who

were believed to be at excessive risk for open surgery, pioneering an alternative procedure known as Thoracic EndoVascular Aortic Repair (TEVAR).

Nowadays a significant number of patients with thoracoabdominal aortic pathologies are unsuitable for TEVAR owing to the absence of graft seal zones. In such situations we rely on the "Hybrid" technique, which include open aortic debranching procedures, allowing the creation of proximal and/or distal landing areas in order to expand the appliance of endovascular repair. This approach was first applied to a patient with Marfan syndrome and a chronic dissection with a Crawford type 2 TAAA at the University of Michigan in December of 1999 because of her insistence in avoiding a redo thoracotomy.

The hybrid concept essentially entails three main principles:

- (I) the open debranching of the great vessels;
- (II) the creation of proper proximal and distal landing zones,
- (III) concomitant or delayed endovascular stent grafting of the aortic aneurysm

The main indications for surgical treatment of thoracic aortic aneurysms (TAAs) are based on: size, growth rate and symptoms. Because the risk of rupture is proportional to the diameter of the aneurysm, aneurysmal size is the main criterion for the elective surgical repair. Elefteriades [1,2] published the natural history of TAAs and recommended the elective repair of descending aneurysms at 6.5 cm for patients without any familial disorders such as Marfan syndrome. In addition, relative aortic aneurysm size in relation to body surface area may be more important than absolute aortic size in predicting complications. Using the aortic size index (ASI)[3] of the aortic diameter (in cm) divided by body surface area (m^2), one can stratify patients into the following three groups:

- ASI $<2.75 \text{ cm}/m^2$ are at low risk for rupture (4%/year)
- ASI $2.75\text{-}4.25 \text{ cm}/m^2$ are at moderate risk (8%/year)
- ASI $>4.25\text{cm}/m^2$ are at high risk (20-25%/year)

In order to summarize the 2010's Guidelines for Use of TEVAR, we strongly

indicate considering the presented technique in situations which imply the following parameters:

- Aortic size - descending aortic diameter $\geq 6.5 \text{ cm}$; subtract 0.5 cm from the cutoff measurement in the presence of Marfan syndrome, family history of aneurysm or connective tissue disorder, bicuspid aortic valve, aortic stenosis, dissection, patient undergoing another cardiac operation; growth rate $\geq 1 \text{ cm}/\text{year}$.
- Symptomatic aneurysm
- Traumatic aortic rupture
- Acute type B aortic dissection with associated rupture, leak, distal ischemia

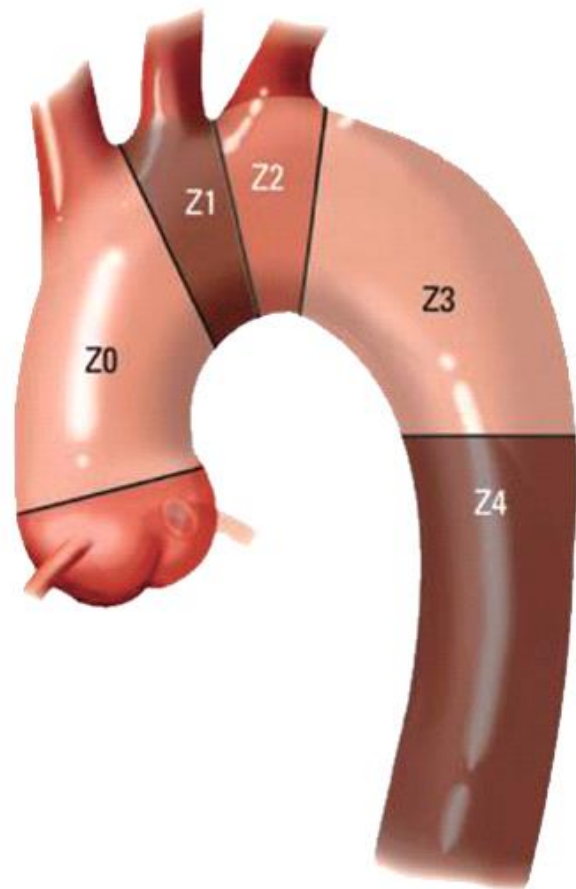


Figure 1 – Aortic Arch Landing Areas

- Pseudoaneurysm
- Large saccular aneurysm
- Mycotic aneurysm
- Aortic coarctation
- Bronchial compression by aneurysm
- Aorto-bronchial or aorto-esophageal fistulas

The key to a successful procedure begins with meticulous preoperative planning to determine the precise size of the endograft, its length and its relation to critical branch vessels.

Typically, TEVAR is performed with the proximal stent graft landing in zones (Z) 2 or 3 [4]. Z3 landing, which is distal to the left subclavian artery (LSCA) takeoff, is suitable for descending mid-thoracic aneurysmal disease or some type B aortic dissections, such as the one discussed in our presented clinical case. For the proximal descending thoracic aortic pathologies (aneurysms or dissections), Z2 landing, covering the LSCA, is required. This may ask for a left common carotid (LCC) to LSCA bypass. In patients with a dominant left vertebral artery, left upper extremity ischemia, or with left internal mammary artery to left anterior descending artery coronary artery bypass grafting, the LCCA to LSCA bypass is a requirement. In such cases the bypass should be performed before the endovascular stent grafting. The main theoretical advantages of the operative technique of “hybrid” or “debranching” thoracic aortic pathology repairs, include obviating the need for thoracotomy in patients with significant pulmonary comorbidity and avoiding prolonged ischemic times associated with open repair.

Case Presentation

In the following paragraph we shall discuss the Endovascular Treatment of a Type B Complicated Aortic Dissection in a patient with Pheochromocytoma and Extensive Coronary arteries diseases.

We present the case of a 48-year-old male, reported smoker, revealing a history of untreated hypertension and exertion angina, describing symptoms such as antero-posterior thoracic pain for the last hour before admission. Explorations revealed blood pressure of 220/110 mmHg, ECG and echo revealed LV hypertrophy, diffuse hypokinesia, EF: 45-50%. The patient's appointment to coronary angiography revealed a LAD with proximal occlusion, CxA with severe stenosis of the Marginal Branch – depicting a possible dissection as well as a RCA without stenosis with retrograde collaterals for LAD.

CT scans (Figure 2) guided us to the complete diagnostic of Stanford Type B Acute Aortic Dissection emerging from the origin of the left subclavian artery to the celiac trunk,

right Suprarenalian Tumor and left pleural effusion. His evolution has been monitored in the following week, the laboratory findings revealed positive urinary metanephrines, a haemoglobine decrease from 12g/dl to 7.5g/dl in only 3 days and a failing treatment of the patient's HBP. A presumptive diagnosis leads us to a first emphasis of Acute Complicated Type B Aortic Dissection associated with Extensive Coronary Disease, suspicion of Pheochromocytoma and 3rd stage hypertension.

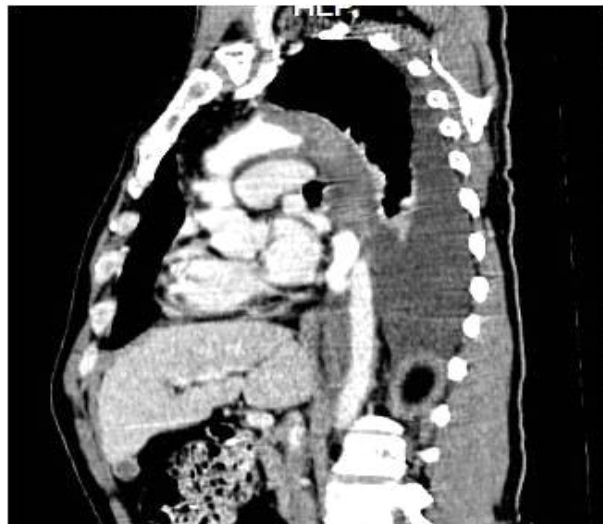

Figure 2 - Patient Sagittal CT scan showing Stanford Type B Aortic Dissection

The HEART Team's decision was to institute strict preoperative antihypertensive treatment followed by hybrid debranching and TEVAR.

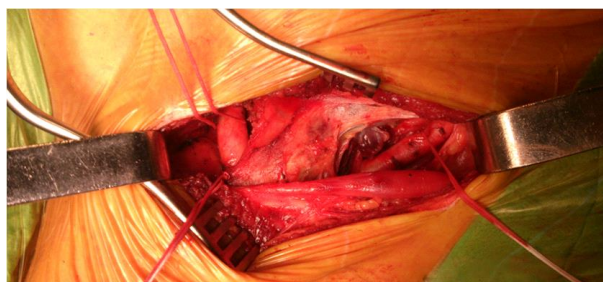

Figure 3 - Classic Intervention revealing Left Subclavian Artery Debranching

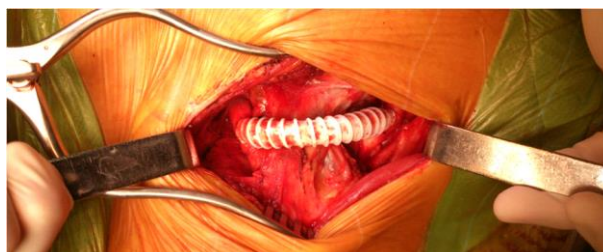


Figure 4 - Stent Graft Placement from the left carotid artery to the left subclavian

First step of the Procedure: Left Subclavian Debranching (Figure 3) . As discussed before, creating stable graft sealing zones allows the surgeon to operate with the full potential of endovascular techniques. The first step consist of an external left carotid to left subclavian artery bypass, made using an 8mm PTFE ringed armed graft, in order to create the Z3 corresponding landing zone as well as to allow the continuous vascularization of the upper left extremity, keeping the integrity of the vertebral artery and of course to avoid any transient ischemic vascular episodes which may occur at the application of the stent graft (episodes which may occur even in patent arteries).

ascending aortic area and a second one from the carotid to the celiac trunk.

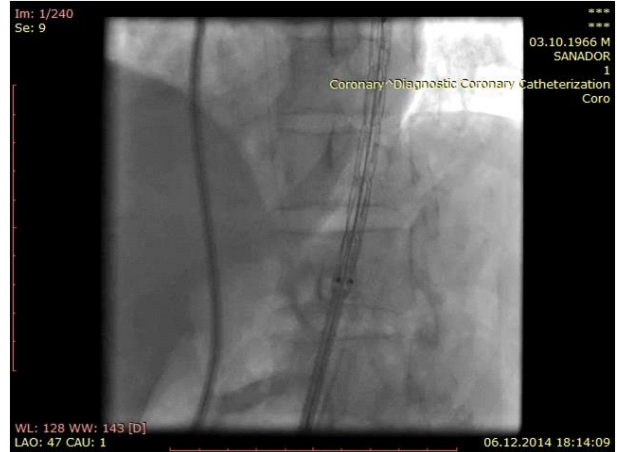


Figure 6 - Angiography revealing permeability of the Stent Graft placement at the left subclavian artery and descending aorta respectively

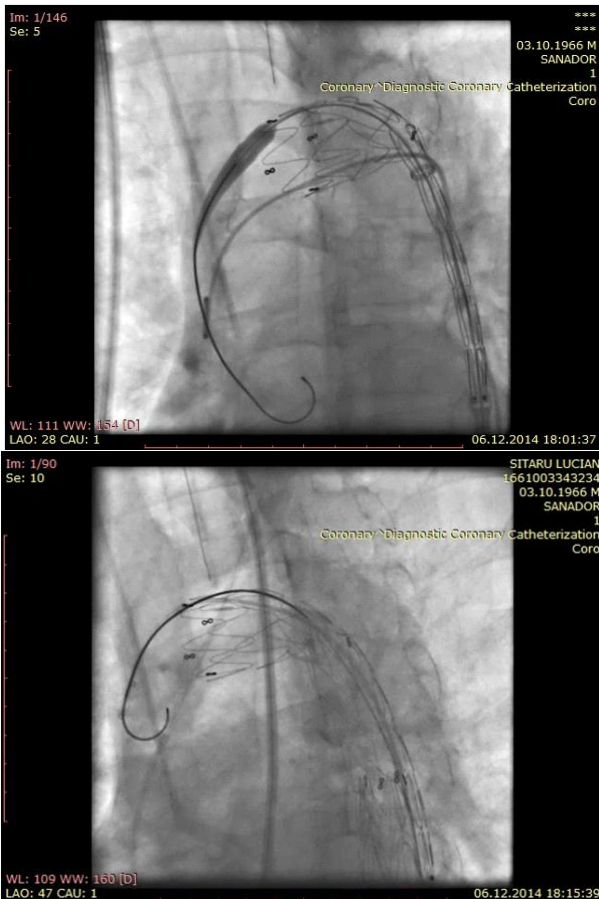


Figure 5 - Angiography revealing permeability of the Stent Graft placement at the left subclavian artery and descending aorta

The second step of the procedure consists of the Interventional Management of the dissection (Figure 4) and is performed by the placement of 2 stent grafts: one originating from the left carotid artery to the left subclavian and

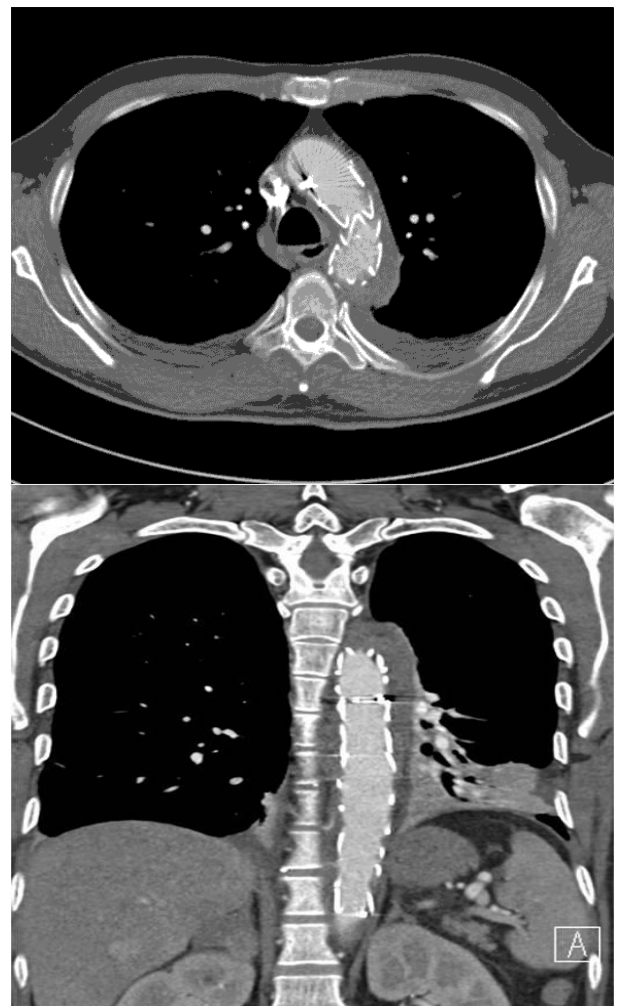


Figure 7 - CT scan revealing the placed stent

The 1st thoracic stent has been implemented at the left subclavian artery level (Figure 5).

The second stent was placed as mentioned below on the trajectory of the descending aorta

until the origin of the celiac trunk has been met. An angiographic control has been made in order to check the patency of the 2 grafts.

The patient's follow-up concluded in the suprarenal tumor resection and confirmation of the pheochromocytoma. One month later, following the prescribed anti-hypertensive treatment the patient becomes asymptomatic and normotensive. The Heart team is currently working to determine when is the right moment to proceed with coronary revascularization and how: either PCI or CABG.

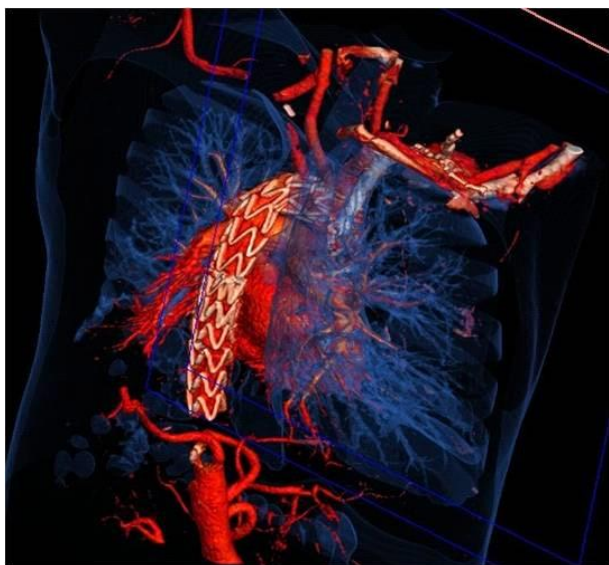

Figure 8 - CT Scan Reconstruction

Results

Unfortunately, since the technique has been recently implemented and continuously adapted on a case by case basis, we do not have results of long term clinical trials or randomized studies, therefore we refer to the clinical outcomes of our patients and the current data that the nonrandomized trials have to offer. Current data from the nonrandomized studies comparing the Endovascular Aortic Repair with the Open Surgical Repair claim reduced perioperative complication rates with similar long-term, but no prospective comparisons are available to date [5]. The overall risk of stroke was similar for TEVAR versus open surgery (OR: 0.75, 95% CI: 0.50 to 1.13). Compared with open surgery, TEVAR significantly reduced risk of: operative mortality (2.1% vs 11.7%) and paraplegia or paraparesis (permanent or temporary) (OR: 0.42, 95% CI:

0.28 to 0.63), renal dysfunction (OR: 0.40, 95% CI: 0.25 to 0.63), reoperation for bleeding (OR: 0.26, 95% CI: 0.11 to 0.62), and incidence of transfusion (OR: 0.01, 95% CI: 0.002 to 0.04). Hospital length of stay was significantly reduced as well as the intensive care unit length of stay was significantly reduced by 4 days [6,7] (Figures 7,8).

Discussions

Comparative analysis suggests that hybrid debranching and endovascular repair of extensive thoracoabdominal pathologies represent a suitable therapeutic option to reduce the morbidity of all abdominal aortic aneurysms and dissection repairs, particularly in high risk patients. TEVAR is associated with reduced morbidity and mortality in the short term. However, no cost benefit was seen with TEVAR even in the short term. In the long term, due to increased risk of re-interventions TEVAR may actually prove to be a more expensive therapeutic option. Open thoracoabdominal aneurysm repair in centers of aortic surgery excellence has very good early results and long-term outcomes. With open repair, there are no aorta-specific anatomical constraints as seen with the endograft repair. The durability of open repair is not in question. Devices for thoracic and thoracoabdominal endovascular repair are improving, however they still have significant limitations and shortcomings to promote wide application of the technique to all patients and pathologies.

Conclusion

The open surgery phase included in the hybrid approach surgeons adopt nowadays is still and will remain of paramount importance in "extending" the possibilities of interventional cardiology.

References

- [1] Hughes GC, Nienaber JJ, Bush EL, Daneshmand MA, McCann RL. Use of custom Dacron branch grafts for "hybrid" aortic debranching during

- endovascular repair of thoracic and thoracoabdominal aortic aneurysms. *J Thorac Cardiovasc Surg*, 2008 Jul, Vols. 136(1):21-8.
- [2] Patel R, Conrad MF, Paruchuri V, Kwolek CJ, Chung TK, Cambria RP., Thoracoabdominal aneurysm repair: hybrid versus open repair. *J Vasc Surg*, 2009, Vols. 50:15–22.
- [3] JA, Elefteriades, Natural history of thoracic aortic aneurysms: indications for surgery, and surgical versus nonsurgical risks. *Ann Thorac Surg*, 2002, Vols. 74(5):S1877-80; discussion S1892-8.
- [4] 2010ACCF/AHA/AATS/ACR/ASA/SCA/SCAI/SIR/STS/SVM Guidelines for the Diagnosis and Management of Patients with Thoracic Aortic Disease: Executive Summary. 2010.
- [5] Prashanth Vallabhajosyula, Wilson Y. Szeto, Nimesh Desai, Caroline Komlo and Joseph E. Bavaria, Type II arch hybrid debranching procedure. *Ann Cardiothoracic Surg*, 2013, Vols. 2(3); 378-386.
- [6] Bavaria JE, Appoo JJ, Makaroun MS, et al., Endovascular stent grafting versus open surgical repair of descending thoracic aortic aneurysms in low-risk patients: a multicenter comparative trial. *J Thorac Cardiovasc Surg*, 2007, Vols. 133(2):369-77. .
- [7] Endovascular Aortic Repair Versus Open Surgical Repair for Descending Thoracic Aortic Disease: A Systematic Review and Meta-Analysis of Comparative Studies. Cheng D, Martin J, Shennib H, et al. s.l.: J Am Coll Cardiol. , 2010, Vols. 55(10):986-1001.