

CLINICAL CASE

TREATMENT OF A COMPLICATED FEMORAL SHAFT NON-UNION USING VASCULARIZED FIBULAR GRAFT - CLINICAL CASE**D. Vilcioiu¹, I. Cristescu¹, A. Ursache¹, D. Zamfirescu², F. Safta¹, A. Stoian², I. Lascar²**¹ The Department of Orthopedics and Traumatology, The Clinical Emergency Hospital of Bucharest, Romania² The Department of Plastic Surgery and Reconstructive Microsurgery, The Clinical Emergency Hospital of Bucharest, Romania

Corresponding author: Ioan Cristescu

Phone no. 040743101049

E-mail: ioancristescu@yahoo.com

Abstract

Free vascularized bone grafts were found to be very effective in segmental bone defect resulted after trauma or wide tumor resection. We present a complex case of a femoral shaft non-union, which was initially treated in other service. After two surgical interventions, both complicated with implant failure after bone non-union, the segmental bone loss was treated in our clinic using free vascularized bone graft. This method was found to be really efficient and the patient was able to walk again after a good rehabilitation program in less than 6 months. Our experience with microvascular transfer of fibular graft has shown that massive autogenous bone grafting with an intact vascular pedicle accelerates the time for bone healing and improves the rehabilitation program. Non-union in long bones after multiple surgical interventions will lead to implant failure and bone loss. The technique has proven reliable in the reconstruction of the bone defect of greater than 6 to 8 cm following defects existing in a fibrotic, avascular bed. Donor site morbidity was negligible. We managed to treat a complicated case of a femoral shaft non-union in an orthoplastic manner using both techniques and principles. Our data suggests that vascularized bone grafts represent a valuable procedure for reconstruction of large segmental bone loss.

Keywords: vascularized fibular graft, reconstructive microsurgery, femoral non-union**Introduction**

Extensive long bone defects have been reconstructed using autogenous/homologous bone grafting [1]. This resulted in prolong time for bone integration, atrophy after bone union leading to fracture and implant failure. The possible explanation might be the incomplete neovascularization of the graft, which leads to a mixture of necrotic and viable bone with reduced strength. The advantage of using vascularized bone graft stands in the combination of viability of cancellous with the

stability brought by cortical graft, along with intact nutrient blood supply [2, 3].

Nowadays the free VFG is a viable method of reconstruction traumatic bone gaps larger than 6 cm in patients who associates soft-tissue defects. Results are best seen if reconstruction is done within 1 week of trauma [4]. Beyond traumatized patients, VFG proved to be useful in treatment of osteomyelitis, bone loss after resection of tumors, kyphosis and congenital pseudoarthrosis [5]. Furthermore autologous fibula grafting is not influenced by immunoreactive mechanisms, which could

interfere with healthy integration of the bone graft [6-8].

Although VFG proved to be a reliable choice of treatment in large bone defects, it brings a number of early and late postoperative complications. Early complications are devascularisation of the donor leg due to fibular artery, infection, sensitivity deficits and late complications as valgus ankle deformity, nonunion, osteomyelitis, fibular fracture. The donor site can suffer from transient palsy of the superficial fibular nerve, contracture of flexor hallucis longus. All this can be prevented with a meticulous preoperative planning, including choosing the proper vessel and the type of fixation devise [3, 5, 9].

Case Presentation

The case of a 45-year-old overweight female which was the victim of a car accident in 2008 suffering a distal third femoral fracture classified by AO/OTA as 32-B2 (We present Figure 1). The fracture was surgically treated in another service by open reduction and internal fixation (ORIF) using a Dynamic Condylar Screw system (Figure 2,3)

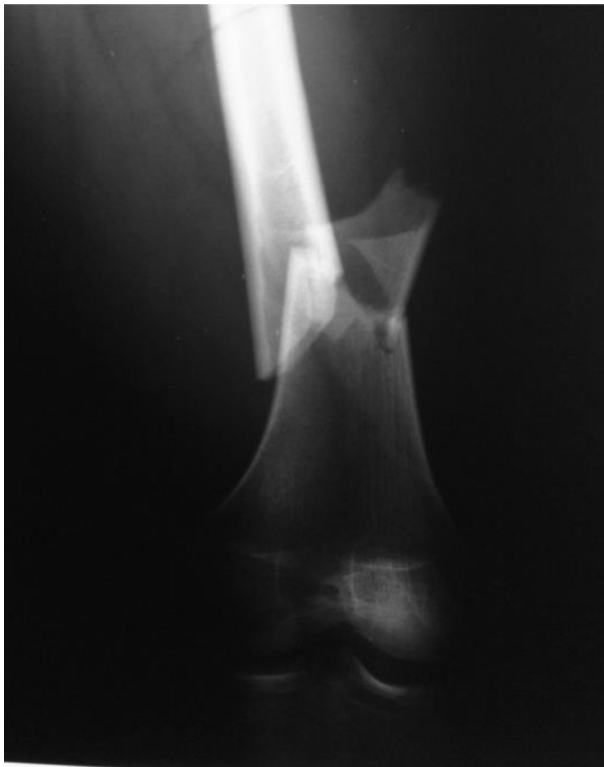

Figure 1 - AP projection of the right knee showing the distal third

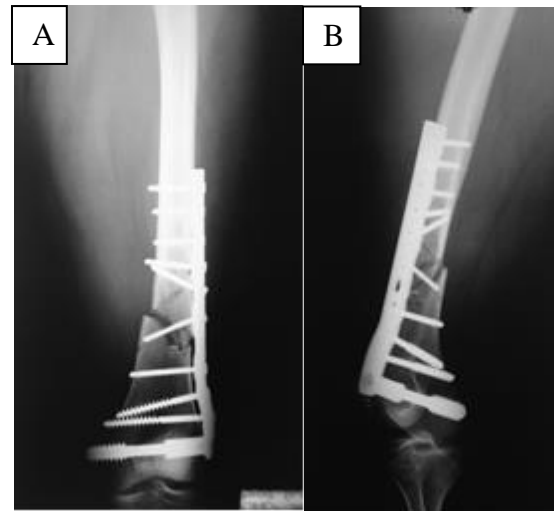


Figure 2 - Postoperative aspect after the first surgical intervention (A- anteroposterior, B- lateral)

Examination highlights the appearance of irrigational callus and implant loosening. The clinical status of the patient got worse with intensive pain and loss of function in the lower limb (Figure 3). They decided to remove the DCS implant and they performed a revision surgical intervention using an intramedullary locked nail, autogenous bone graft and bone substitutes.

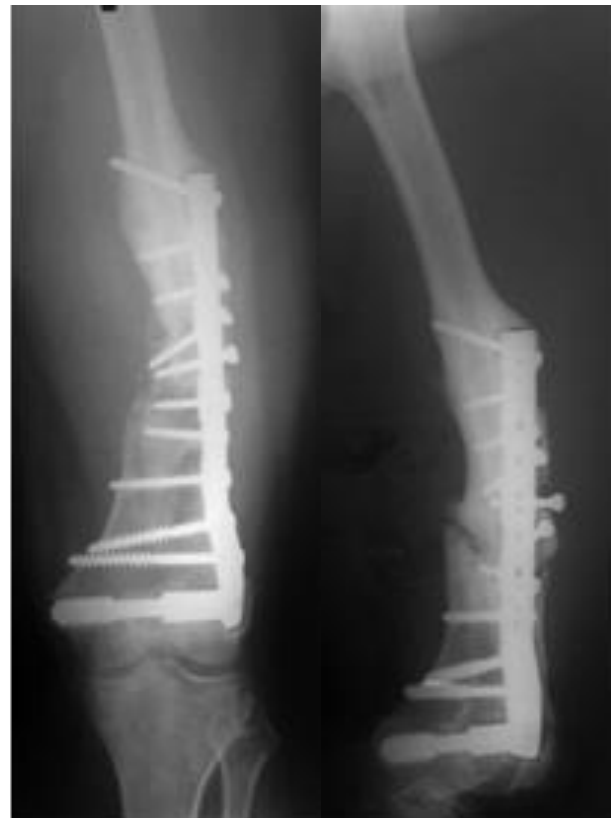

Figure 3 - Radiological aspect showing non-union and implant loosening. (A. A-P view; B. lateral view)

The postoperative aspect of the X-rays demonstrates that the fracture was poorly reduced with interfragmentary gap by malposition of the lag screw (Figure 2). After 9 months the patient developed atrophic non-union with axial deformity with a progressive negative clinical impact. After 1 year, the radiological examination highlights the appearance of irrigational callus and implant loosening. The clinical status of the patient got worse with intensive pain and loss of function in the lower limb (Figure 3). They decided to remove the DCS implant and they performed a revision surgical intervention using an intramedullary locked nail, autogenous bone graft and bone substitutes.

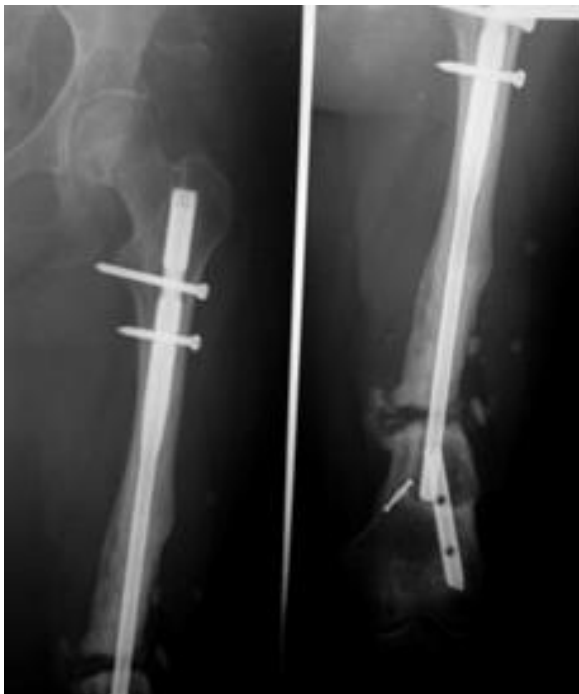

Figure 4 - AP view and lateral view of the affected femur showing implant failure

The bone defect was significant this time and the bone grafts and substitutes were not enough for filling it. Thus, the patient started partially weight bearing for 1 month until the implant was broken (Figure 4). In this situation the patient came to our service and we used an interdisciplinary approach for planning and treating this case of femoral shaft non-union with a low local vascular status and massive bone defect.

We planned very carefully the third surgical intervention for the patient with lower limb angiography, computed tomography (CT), blood supply and full patient compliance. In our

service we use an orthoplastic approach of each patient, which includes both principles and practices for best bone fixation and soft tissue coverage. This way, we were able to remove the broken implant- IM locked nail and the avascular tissues, including sclerotic bone. We used a free vascularized fibular graft, which was harvested from the ipsilateral leg by the plastic surgery team and fixed by the orthopedic team using a Less Invasive Stabilization System (LISS) Plate (Figure 5).

Despite the large fibular defect, the donor site morbidity was negligible due to the fact that the middle third of the fibular is not involved in the biomechanical processes of the lower limb (Figure 6).

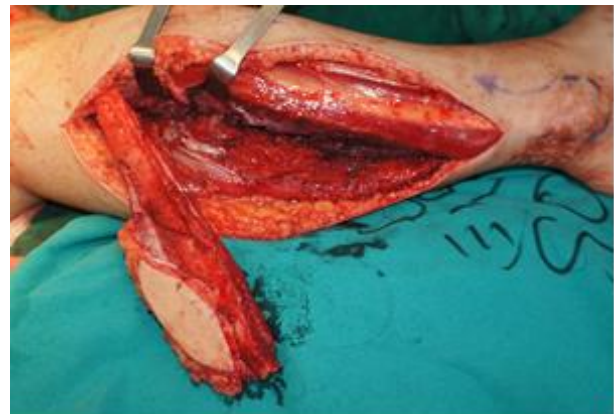

Figure 5 - The fibular graft just before the pedicle is transferred to the femoral area

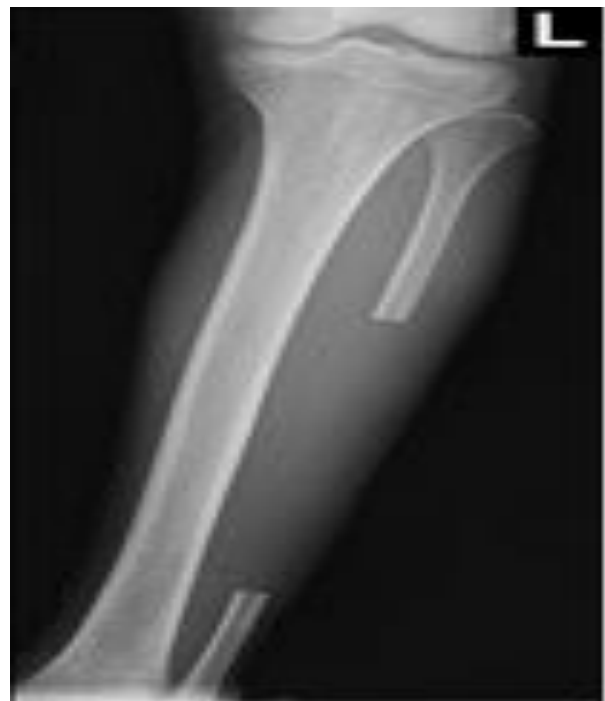

Figure 6 - Radiological aspect of the donor site

This way we were able to restore the femoral length and axial deformity, to fill the massive bone defect with the fibular graft and to restore the local vascularization (Figure 7).

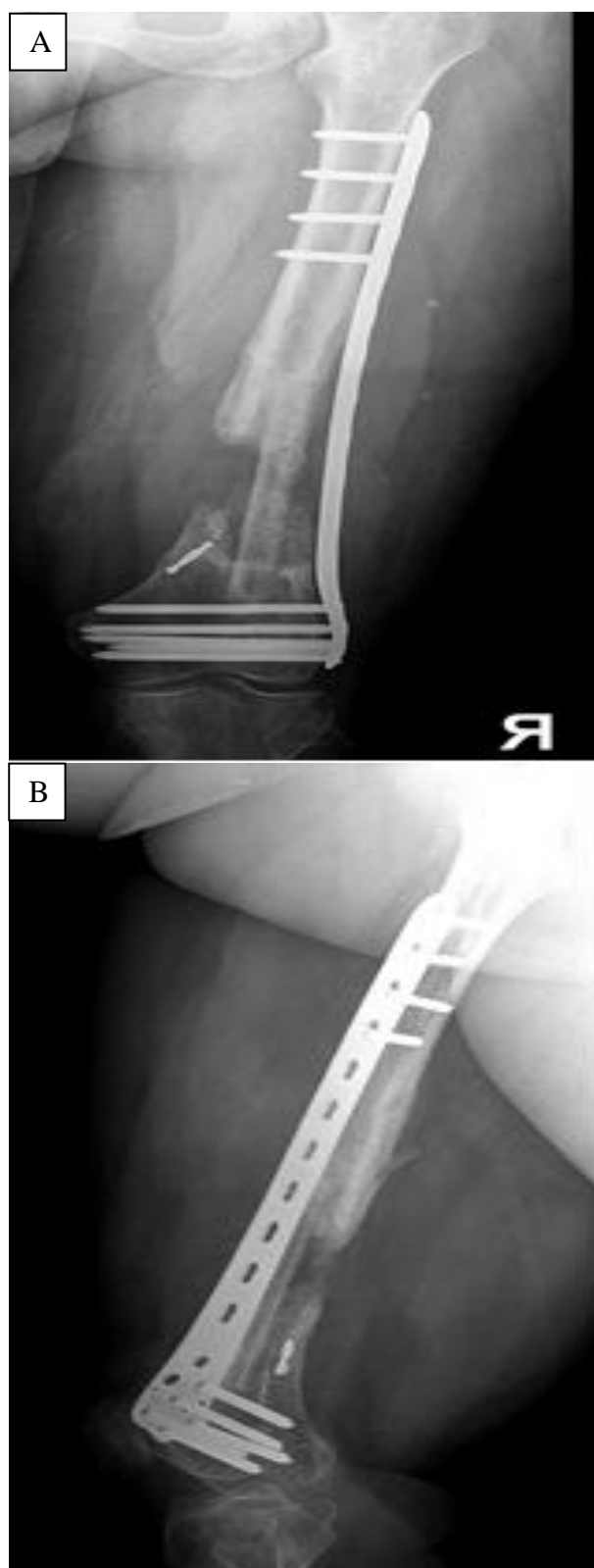


Figure 7 - Postoperative aspect of the VFG fixed with LISS plate. (A. A-P view; B. lateral view)

After 2 years being in our evidence, the patient is completely recovered using full weight bearing. The radiological aspect is showing that the fibular graft got thicker and the long axis of the femur is intact in both planes, the frontal and the sagittal one.

Discussions

Fractures of the femoral shaft are mostly the result of high-energy trauma and condition which is frequently accompanied by sequelae as limb shortening, poor alignment and nonunion, knee stiffness [10]. Within trauma, beside the bones, the high amount of kinetic energy is able to induce great damage to the soft tissues which needs an adequate management plan for reducing the morbidity and mortality associated with this condition [11]. Diaphyseal femur fractures have an incidence between 9.9 and 12 for 100.000 persons/year, 60% occur in men and 40% in women, with a maximum incidence in youth, mainly due to traffic accidents [10].

Vascularization and adjacent muscles are two important actors in the physiopathology of fracture consolidations. Both suffer important damages after high-energy trauma. The importance of vascularization in osteogenesis is explained by initially formation of granulation tissue consisting of connective tissue and small blood vessels. The surrounding soft tissue of the fracture provides an important vascular source which delivers oxygen, nutrients and potential osteoprogenitor cells. Furthermore, callus formation tends to be best represented at the interface between bone and muscle due to muscle ability to augment periosteal supply and increasing osteogenic potential [12].

In our patient, several factors contributed to developing a fibrotic and avascular bed: high-energy trauma, patient obesity, closed femur fracture, two failed attempts to reduce the fracture (first by open reduction and internal fixation using DCS system with ten screws; second by intramedullary fixation). All this led to developing a bone defect, after pseudarthrosis, which could have been managed by external fixation and bone transport (the patient obesity was a contraindication), allograft transplant of vascularized fibular graft. From those three

therapeutic options we concluded that the last one is suitable for our patient.

Conclusions

By merging the principles of orthopedic surgery with plastic surgery a concept known as orthoplastic surgery was born. In our case, the orthopedic team excised the nonviable bone tissue and fixed with a special plate the vascularized fibular graft after harvesting and suturing the vascular pedicle to the femoral vessels by the plastic surgery team. Considering that the prior surgical intervention the patient had resulted in an absolute functional impotence, allowing the patient to walk again and the radiological integration of bone graft are successful arguments to use VFG in large bone defects.

High-energy trauma of inferior limb, obesity, multiple failed attempts of femur reduction may favor developing non-union of bones and large defects. We manage to treat with success in an orthoplastic manner a large femur defect, after pseudarthrosis, using vascularized fibular graft.

References

- [1]Malizos, K. N., Beris, A. E., Xenakis, T. A., Korobilias, A. B. & Soucacos, P. N. Free vascularized fibular graft: A versatile graft for reconstruction of large skeletal defects and revascularization of necrotic bone. *Microsurgery* 13, 182–187 (1992).
- [2]Hiroshi Yajima et.al. Vascularized fibular grafts for reconstruction of femur. *J Bone Surg [Br]* 1993; 75-B:123-8.
- [3]Tu, Y. K. et al. Reconstruction of posttraumatic long bone defect with free vascularized bone graft: good outcome in 48 patients with 6 years' follow-up. *Acta Orthop Scand* 72, 359–364 (2001).
- [4]Kalra, G. S., Goel, P. & Singh, P. K. Reconstruction of post-traumatic long bone defect with vascularised free fibula: A series of 28 cases. *Indian J Plast Surg* 46, 543–548 (2013).
- [5]Minami, A., Kasashima, T., Iwasaki, N., Kato, H. & Kaneda, K. Vascularised fibular grafts. An experience of 102 patients. *J Bone Joint Surg Br* 82, 1022–1025 (2000).
- [6]Xenakis, T. H. et al. Vascularised bone grafts in the treatment of long bone defects. *Microsurgery* 15, 479–484 (1994).
- [7]Chen, C. M. et al. Reconstruction of extremity long bone defects after sarcoma resection with vascularized fibula flaps: a 10-year review. *Plast. Reconstr. Surg.* 119, 915-924-926 (2007).
- [8]Erni, D., De Kerviler, S., Hertel, R. & Slongo, T. Vascularised fibula grafts for early tibia reconstruction in infants with congenital pseudarthrosis. *J Plast Reconstr Aesthet Surg* 63, 1699–1704 (2010).
- [9]Iamaguchi, R. B., Fucs, P. M. M. B., da Costa, A. C. & Chakkour, I. Vascularised fibular graft for the treatment of congenital pseudarthrosis of the tibia: long-term complications in the donor leg. *Int Orthop* 35, 1065–1070 (2011).
- [10]Rodriguez-Merchan, E. C., Moraleda, L. & Gomez-Cardero, P. Injuries Associated with Femoral Shaft Fractures with Special Emphasis on Occult Injuries. *Arch Bone Jt Surg* 1, 59–63 (2013).
- [11]Jovanović, M., Janjić, Z. & Marić, D. [Principles of management of high-energy injuries of the leg]. *Med. Pregl.* 55, 437–442 (2002).
- [12]Davis, K. M. et al. Muscle-bone interactions during fracture healing. *J Musculoskelet Neuronal Interact* 15, 1–9 (2015).