

## THE MANAGEMENT OF A RARE BREAST TUMOR IN PREGNANCY

**Alexandra Vintea<sup>1</sup>, Romina Sima<sup>2</sup>, T. Burcoş<sup>3,4</sup>, G. Bănceanu<sup>1,4</sup>, Oana Toader<sup>1,4</sup>**

<sup>1</sup>The National Institute for Mother and Fetal Health “Alessandrescu Rusescu”, Polizu Maternity, Bucharest, Romania

<sup>2</sup>“St John” Hospital, “Bucur” Maternity, Bucharest, Romania

<sup>3</sup> Coltea Clinical Hospital, The Surgery Department, Bucharest, Romania

<sup>4</sup> The University of Medicine and Pharmacy “Carol Davila”, Bucharest, Romania

Corresponding author: Romina Sima

Phone no. 0040741071243

E-mail: romina.sima@yahoo.es

### Abstract

*The incidence of breast cancer in pregnancy is expected to occur more frequently because of delaying childbearing until later in life. The suspicion index must be very high for a diagnosis in a case of a breast tumor which appears in pregnancy, and postponing the diagnosis may impact the patient survival and quality of life. In the below article we will present the case of a 29-year-old woman who was admitted in our clinic after the appearance of a tumor in her left breast. The patient is 23 weeks pregnant and the tumor appeared at 16 weeks of gestation. She denies other pathologic affections. The clinical and ultrasound examination of the breast revealed the volume of left breast 2 times bigger than the right one, with intense Doppler signal. Fine needle aspiration and core biopsy were performed and the result was not very conclusive. The patient wants to continue the pregnancy and she disagrees with further procedures during the gestation period. She delivers by elective C-Section at 36 weeks of gestation a healthy, 2300 grams girl. Two weeks after the delivery and after inhibition of lactation, wide local excision of the disease was performed and 2 tumors were extracted (first 7/4/2.5 cm; second 18/16/8 cm, both of them with firm consistency and with white-yellowish color). The histology was Phyllodes tumor with myxomatous areas. The postoperative evolution was favorable without any recurrence until now.*

**Keywords:** breast tumor, phyllodes tumor, pregnancy

---

### Introduction

The diagnosis of a breast tumor in pregnancy represents a challenging situation because on one side, the physiological changes of the pregnancy confuse the clinical manifestations and, on the other side, the diagnostic investigations and procedures are somehow limited by their potential harm to the fetus. The suspicion must be very high because breast cancer in pregnancy will become more frequent as more and more women postpone childbearing until advanced ages. Phyllodes

tumor represents 1% of breast tumor [1]. They arise from the connective tissue of the breast. Their clinical manifestation may be very scary because they have a rapid growth pattern which can mimic an aggressive cancer.

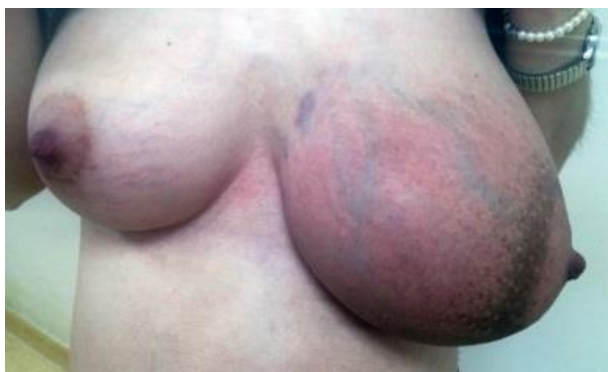---

### Case presentation

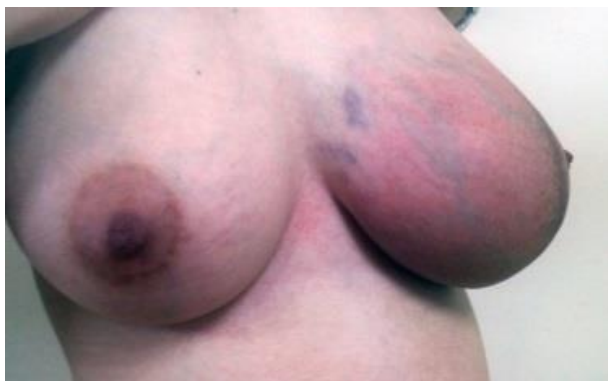The patient S.M. 29-years-old was admitted to the hospital for investigation a breast tumor which appeared for 2 months. The patient was 23 weeks pregnant after the last

menstrual period, she denied other pathologic affections; the breast tumor was observed for the first time at 16 weeks when the breast began to grow progressively.

The clinical examination revealed the left breast transformed into a tumor, with its volume 2 times bigger than the right breast. The tumor was endured, poorly delimited, 7/6 cm, painless, with the blood vessels very well represented and the overlying skin of an orange-peel appearance. No axillary lymphadenopathy was found (Figures 1 and 2).



**Figure 1 – Initial clinical examination**



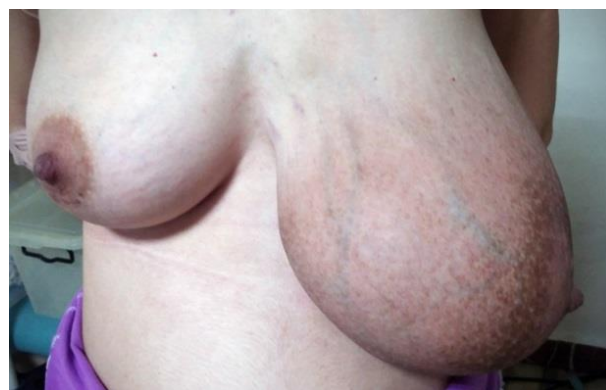**Figure 2. – Initial clinical examination**

The breast ultrasound scan identified an extended tumor to all 4 quadrants of the breast, well delimited, with no adherence to tissue nearby (pectoral muscles or skin) with Doppler signal and without axillary lymphadenopathy. The contralateral breast scan showed normal parenchyma, without tumors or duct ectasia. The obstetrical ultrasound revealed in the uterine cavity a unique fetus, apparently normally conformed for 23 weeks 5 days. The hematological examination was in normal range, with a low pregnancy physiologic anemia. During the admission the patient underwent fine needle biopsy and core biopsy for the breast tumor. After the cytologic result (superficial

squamous cells and glandular cells, some of them with dyskaryosis) the suspicion of inflammatory breast cancer was raised. The patient wanted to wait for the core biopsy result before any other diagnosis or therapeutic procedures. The core biopsy revealed glandular adenomatous hyperplasia, myoepithelial hyperplasia, pericanalicular fibroadenoma and a little isolated fragment of squamous acanthosis. The therapeutic options were explained to the patient: the surgical procedure for the left breast tumor (wide local excision with extemporaneous histology) and, in case of confirmed malignancy, the oncologic treatment, or, the continuation of pregnancy until term and surgical procedure for the breast after delivery. She chose the last option. Written informed consent was obtained from her.

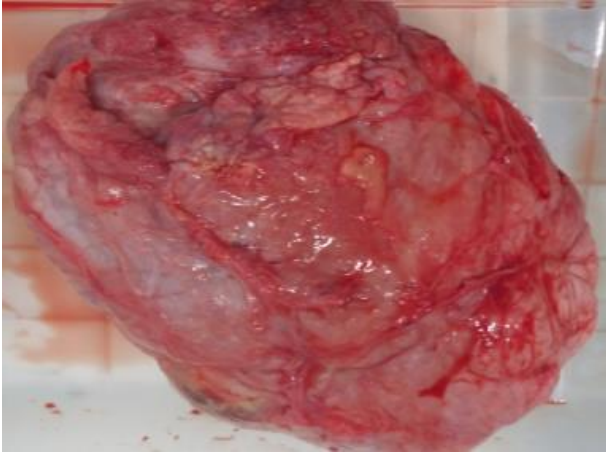
At 28 weeks of gestations a breast ultrasound scan was repeated and the same characteristics as the first scan were observed. We asked for an oncologic opinion via telephone and we were informed that the pregnancy should continue till term (around 36-37 weeks of gestation) and, the surgical procedure for the breast should be done after delivery.

At 36 weeks of gestation the patient delivered via elective C-Section a healthy baby, sex feminine, weight 2300grams, Apgar score- 9. Postoperative follow up was favorable. Besides the usual treatment (antibiotics, low weight molecular heparin, pain killers), drugs for lactation suppression were given (Bromocriptine 2,5 mg b.i.d. for 10 days). Two weeks after delivery the clinical breast examination revealed almost the same characteristics as the antepartum ones, but with visible progressive growth of the tumor (Figure 3).

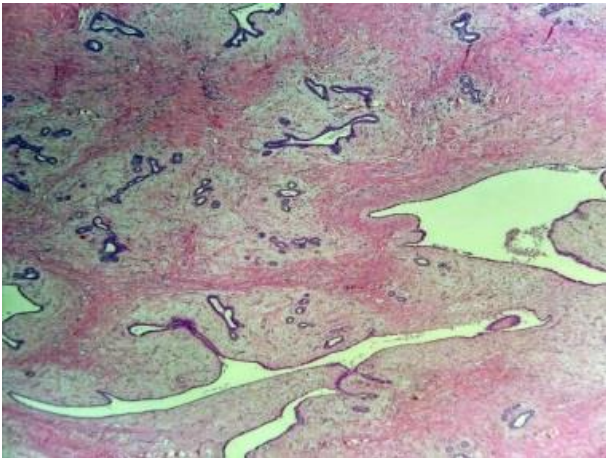


**Figure 3. – Preoperative aspect (the tumor grew visible during pregnancy)**

We performed a wide local excision. An elliptic incision was made at the level of the inferior quadrants of the left breast. Two tumors were extracted from the left breast: first 7/4/2.5 cm and second 18/16/8 cm (Figure 4), both of them with firm consistency and white-yellowish color. Both of them were sent to extemporaneous histology and the result was phyllodes tumor with myxomatous areas (Figures 5).



**Figure 4 - The gross appearance of the tumor**



**Figure 5 - Microscopic appearance (leaf like pattern)**

Because of the benign result, the surgical procedure was finished after the bleeding control and the soft tissue closing, with a drain tube which was drawn 5 days postoperatively.

The postoperative evolution was favorable, without significant events. The patient was discharged 7 days after the second surgical procedure. The patient made the visits according to our recommendations and she had no complaints and no pathology according to the clinical examination. Until now, the patient did not suffer any tumor recurrence.

## Discussions

The Phyllodes tumors are rare and represent 1% of all breast tumors [1]. The etiology of phyllodes tumors is not truly known. The name originates from Greek (the word phyllon means leaf) because of the projections of stroma between the ducts thus creating a leaf like pattern [2].

The phyllodes tumor appears almost exclusive in female. They can develop in any age, but a higher frequency was observed in the fifth decade.

A phyllodes tumor can look like fibroadenomas. They both appear from intralobular fibrous tissue and after a period of time they can differentiate in two directions: to fibroadenoma or to phyllodes tumors. They both have similar histology in the beginning and the different growth starts later, especially in the connective tissue [3]. Compared to fibroadenomas, the stromal fragments of phyllodes tumors are larger and hypercellular [4].

The stromal component can vary significantly in histologic appearance from one lesion to another and thus, the tumors are classified into benign, borderline and malign. This classification takes into consideration tumor margins, stromal cellularity and overgrowth, tumor necrosis, cellular atypia and the number of mitoses per high power field [1]. The benign phyllodes tumors usually do not metastasize, but they tend to grow aggressively and can recur locally [1]. Macroscopically, the tumor can grow to more than 20 cm. Small tumors have a white consistency, similar to the fibroadenomas. The large tumors have a red or grey "meaty" appearance with areas of cysts and necrosis [1].

Microscopically, phyllodes tumors appear as epithelium lined with cystic spaces into which projects a hypercellular stroma. For diagnose confirmation it is necessary the presence of both the stromal and the epithelial components [1].

Phyllodes tumor usually presents as a breast lump which tend to grow very quickly, within a period of weeks or months. The lump is firm, mobile, painless and well circumscribed. The overlying skin may appear shiny and translucent enough to show the underlying veins,

or, in rare cases the tumor may erode through the skin and present as ulcerating breast mass [5].

There are no specific laboratory findings, including tumor markers for the diagnose of the Phyllodes tumor.

The differential diagnosis for phyllodes tumor is first of all with fibroadenoma. Malignant phyllodes tumor mimic the sarcomas of the breast. Other findings are periductal stromal tumor, metaplastic carcinoma, sclerosis adenosis, radial scar, fibrocystic change [6].

The first approach in investigating the lesion is by mammography (the tumors are well defined with a smooth and occasionally lobulated border [7]) and ultrasonography (tumors are often characterized by smooth contours with low level internal echoes, intramural cysts and they do not present posterior acoustic enhancement [7,8,9]). No reliable imagistic indicators have been identified to differentiate between benign and malign lesions of from fibroadenomas; therefore, findings on imaging scans are not to be considered definitive for diagnostic of phyllodes tumors [9].

The definitive method for diagnosing phyllodes tumor is biopsy. Fine needle aspiration (FNA) is usually insufficient. Core biopsy is more reliable and it may still be difficult to differentiate the tumor from a fibroadenoma [10].

Wether it is benign, borderline or malignant, the surgical management of Phyllodes tumor is represented by wide excision without axillary staging.

If the tumor is considered to be sufficiently high to exclude a satisfactory cosmetic result with wide local excision, total mastectomy, with or without reconstruction, should be taken into consideration. Regarding the margin size, the excision should be made with the aim of obtaining surgical margins larger than 1 cm. Mastectomy is not an absolute indication when wide excision or partial mastectomy fails to achieve margin width wider than 1 cm [11].

The postoperative complications are represented by infection, local or distant recurrence and seroma formation. There is no specific consensus regarding the follow up care because of lack of cases. It is recommended that

the first visit should take place 1-2 weeks after surgery for detecting the initial complication. Then, follow up include physical examinations every 6 months for the first 5 years and mammograms annually for the same period of time. Close attention should be paid for local recurrence.

---

## Conclusions

We presented a case of phyllodes tumor which appeared in pregnancy and mimicked an inflammatory breast cancer. The biopsy was inconclusive. Because of the pregnancy, the patient did not want to pursue further investigations. The final diagnostic was made after delivery when the wide local excision was performed with extemporaneous histology of the tumor. The particularity of this case is that the phyllodes tumor is a rare tumor of the breast and it appeared during pregnancy.

---

## References

- [1]Parker SJ, Harries SA. Phyllodes tumours. *Postgrad Med J*. 2001 Jul. 77(909):428-35.
- [2]Klatt EC. Robbins and Cotran Atlas of Pathology. Elsevier Saunders, 2006
- [3]Al-Masri M, Darwazeh G, Sawalhi S, Mughrabi A, Sughayer M, Al-Shatti M. Phyllodes Tumor of the Breast: Role of CD10 in Predicting Metastasis. *Ann Surg Oncol*. 2011 Oct 18.
- [4]R Bandyopadhyay, D Nag, Sk Mondal, S Mukhopadhyay, S Roy. Distinction of phyllodes tumor from fibroadenoma: Cytologists' perspective. *J Cytol*. 2010 Apr; 27(2): 59-62.
- [5]Nabi J, Akhter SM, Authoy FN. A case of large phyllodes tumor causing "rupture" of the breast: a unique presentation. *Case Rep Oncol Med*. 2013. 2013:871292.
- [6]S Lakhani, IA Elis, SJ Schnitt, PH Tan, MJ van de Vijver. WHO Classification of Tumours of the Breast. International Agency for Research on Cancer, Lyon, 2012
- [7]Buchberger W, Strasser K, Helm K, et al. Phylloides tumor: findings on mammography, sonography and aspiration cytology in 10 cases. *Am J Roentol* 1991;157:715-19

- [8]Umpleby HC, Guyer PB, Moore I, et al. An evaluation of the preoperative diagnosis and management of cystosarcoma phyllodes. *Ann R Coll Surg Engl* 1989;71:285– 8
- [9]Cole-Beuglet C, Soriano R, Kurtz AB. Ultrasound, x-ray mammography, and histopathology of cystosarcoma phylloides. *Radiology*. 1983 Feb. 146(2):481-6.
- [10]Yasir S, Gamez R, Jenkins S, Visscher DW, Nassar A. Significant histologic features differentiating cellular fibroadenoma from phyllodes tumor on core needle biopsy specimens. *Am J Clin Pathol*. 2014 Sep. 142(3):362-9
- [11]Clinical Practice Guidelines in Oncology. Breast Cancer. NCCN Evidence Blocks. Version 2.2016