

CLINICAL CASE

SURGERY FOR PRIMARY HYPERALDOSTERONISM - RELATED TUMOUR: LONG TERM OUTCOME AND CO-MORBIDITIES**Adina Ghemigian^{1,2}, Mara Carsote^{1,2}, Simona Elena Albu^{1,3}, Ana Valea^{4,5}**¹The University of Medicine and Pharmacy "Carol Davila", Bucharest, Romania²C.I.Parhon National Institute of Endocrinology, Bucharest, Romania³University Emergency Hospital, Bucharest, Romania⁴The University of Medicine and Pharmacy "I. Hațieganu", Cluj-Napoca, Romania⁵The Clinical County Hospital, Cluj-Napoca, Romania

Corresponding author: Mara Carsote

Phone no. 0040213172041

E-mail: carsote_m@hotmail.com

Abstract

Primary hyperaldosteronism (PH) caused by an aldosterone producing adrenal tumour is cured after adrenalectomy. However, long term follow-up is needed focusing on arterial hypertension and metabolic complications. A 69-year-old male was confirmed with PH at the age of 62. At that moment he had an 18-year history of high blood pressure (maximum 200/100 mmHg) in association with diabetes mellitus and hyperlipidemia. He developed hypopotassemia requiring spironolactone. No hypoaldosteronism was registered but a normalization of adrenal endocrine profile. While the patient was first evaluated for PH at the age of 62, a routine thyroid check-up showed multinodular enlargement with a large cyst on the right lobe. Six years later, the patient has moderate high blood pressure values controlled under daily 80 mg of telmisartan. This is a 49-year-old female with irrelevant family history who became hypertensive at the age of 37. At the age of 42, while she was investigated for performing a cholecystectomy, a left adrenal tumour of 1.2/0.9/0.9 cm was discovered at CT. Three years later she was investigated for secondary hypertension after associating mild hypopotassemia. A tumour production of aldosterone was linked with the adrenal mass. Currently, 4 years after the adrenal excision, biochemistry and endocrine panel is normal with residual high blood pressure controlled with low doses of calcium and beta adrenergic blockers. Surgery for adrenals in primary hyperaldosteronism is one elegant option which may cure the condition. A high index of suspicion and a systematic approach are useful in identifying and proving the diagnosis. Association with other endocrine disorders diversify the clinical appearance. Delaying the diagnosis and adrenalectomy decreases the chance of high blood pressure remission after adrenal removal.

Keywords: *primary hyperaldosteronism, arterial hypertension, adrenalectomy***Introduction**

Primary hyperaldosteronism (PH) represents a well-known cause of aldosterone induced high blood pressure in addition to hypokalemia and

suppressed plasma renin activity (PRA) [1]. Hyperglycemia or frank diabetes mellitus is caused by potassium-dependent insulin secretion impairment due to low potassium [2]. PH is attributed to bilateral adrenal hyperplasia

or aldosterone-producing adenoma [1,2]. The treatment of PH depends on the underlying cause: a single benign tumour requires adrenalectomy, usually performed by laparoscopy (which is curative) while bilateral hyperplasia is medically treated [1-3]. To control hypertension prior to surgery, aldosterone antagonists like spironolactone also improve the metabolic complications of PH, such as plasma glucose profile, and the quality of life [3,4]. PH is rarely found in association with others endocrine tumours as Cushing's syndrome or primary hyperparathyroidism, a kind of multiple endocrine neoplasia which need different types of surgical approaches but also incidental thyroid diseases have been cited [5,6]. The multi-nodular nontoxic goitre is described in PH patients and its prevalence seems to be higher in females than in males [5-7]. The relationship between PH and thyroid nodules is unclear, but common pathogenesis mechanisms, like an imbalance between various growth factors and cytokines, are potentially involved [7]. We present two cases with long-term outcome before and after adrenalectomy for PH and one of them also needed thyroidectomy.

Materials and Methods

This is a cases series. The patients signed the informed consent. They were followed in two Romanian tertiary centres of endocrinology, from Cluj-Napoca, respective Bucharest, Romania.

Case report 1

A 69-year-old non-smoking male, with positive family history for hypertension (father), was first hormonally evaluated at the age of 62 for high blood pressure. At that moment, he had diabetes mellitus treated with oral anti-diabetic drugs, hyperlipidemia, and bilateral renal cystic nodular prostatic hyperplasia. Severe arterial hypertension was first confirmed on a primary health care unit 18 years before. He had hypertensive peaks of 200/110 mmHg before receiving calcium blockers. On admission (at the age of 62), laboratory tests showed low

blood potassium levels (of 3.1 mmol/L, normal between 3.7 and 5.4 mmol/L), normal upper values of serum sodium (of 147 mmol/L, normal between 136-145 mmol/L), and low levels of 24-hours urinary potassium (of 106.8 mmol/24-h, normal between 25-125 mmol/24-h). Hypokaliemia raised the suspicion of PH and abdominal CT (computed tomography) showed a solid right adrenal mass of 1.0 by 2.2 cm (centimetre), consistent with Conn's syndrome in association with serum and urinary aldosterone assays (Table 1). Glucocorticoid axes and urinary metanephrines were also assessed for differential diagnosis of arterial hypertension and adrenal tumour (Table 1).

Parameter	Patient's value	Normal Limits	Units
Before adrenalectomy			
Plasma aldosterone	36.4	1.76-23.2	ng/dL
Urinary aldosterone	37.0	1.19-28.1	µg/24h
Renin	0.9	2.8-39.9	µUI/mL
Plasma Aldosterone /renin ratio	40.4	<3.7	
Urinary free cortisol	759.04	100-379	nmol/24h
Urinary metanephrines	84	<375	µg/24h
After right laparoscopic adrenalectomy			
Serum Na (sodium)	139*	136-145	mmol/L
Serum K (potassium)	5.9*	3.7-5.4	mno/L
Total plasma cholesterol	264	<200	mg/dL
Plasma triglycerides	210	<150	mg/dL
Plasma aldosterone	12.2**	1.76-23.2	ng/dL
Urinary aldosterone	16.4**	1.19-28.1	µg/24h
Plasma morning cortisol	170.7	172-497	nmol/L
Urinary free cortisol	126	100-379	nmol/24h

Table 1 - Biochemical and hormonal profile of a 69-year-old male diagnosed and operated for a Conn's syndrome caused by a right adrenal

tumour; laparoscopic adrenalectomy was performed at the age of 62

Right adrenalectomy was indicated and performed three months later by laparoscopic approach. The procedure went well without any incidents. The pathological report confirmed PH, revealing mainly clear cells with abundant intra-cytoplasmic lipid droplets in association with atypical cells characterized by nuclear enlargement and hyperchromasia. He was hospitalized for 7 days. After discharge, the patient continued antihypertensive treatment, including daily 75 mg (milligrams) of spironolactone for one more month. One month later, blood pressure began to decline and anti-hypertensive medications were gradually tapered. No hypoaldosteronism was registered but a normalization of adrenal endocrine profile (Table 1).

While the patient was first evaluated for PH at the age of 62, a routine thyroid check-up was done and ultrasound showed a global enlargement, with hyperechoic pattern, and multiple nodules, one of them with a large cystic appearance located on the right lobe (Figures 1A,1B). He had normal thyroid function (Table 2). One year later (after patient's surgical approach for Conn's syndrome) the re-evaluation showed increased cyst size of the right lobe and presence of bilaterally larger nodules so total thyroidectomy was performed and confirmed benign aspects.

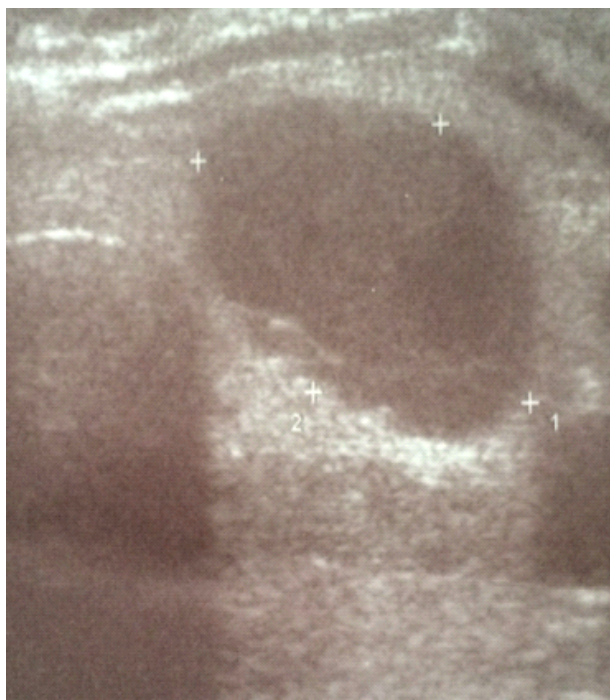


Figure 1A - Saggital section: nodular hypoechoic mass on the right thyroid lobe

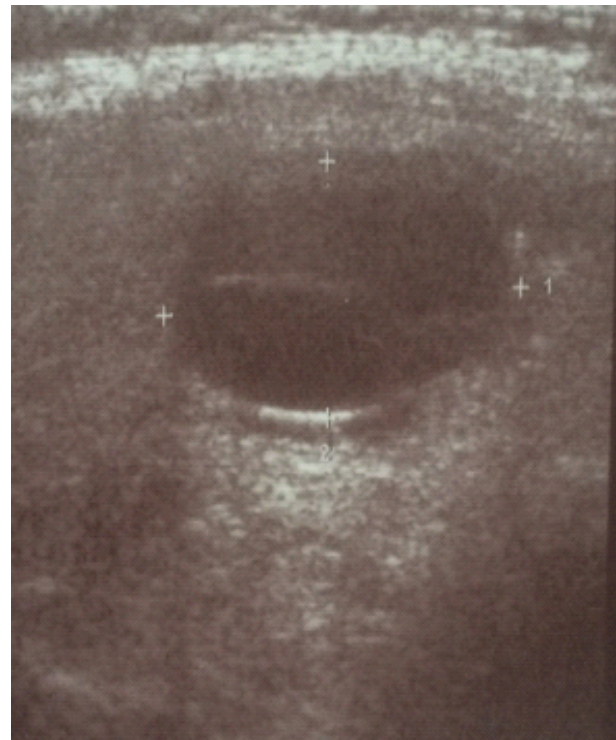

Figure 1B - Longitudinal section: hypoechoic nodule with posterior acoustic enhancement on the right thyroid lobe

Parameter	Patient's value	Normal Limits	Units
TSH (Thyroid Stimulating Hormone)	2.53	0.4-4	μUI/mL
FT4 (FreeT4)	11.6	10.6-22.7	pmol/L
TPOAb	9	<34	UI/mL
TgAb	<10	< 115	UI/ml
Blood calcitonin	3	<14.3	pg/mL

Table 2 - Thyroid endocrine panel on a 62-year-old male with multinodular goitre and right aldosterone producing tumour

Within the first year after adrenalectomy, a better control of diabetes mellitus was achieved revealed by post-operative glycated haemoglobin of 5.9% compared with pre-operative value of 6.5% (normal levels between 4.8 and 5.6%) which allowed Metformin dose reduction from 1500 to 1000 mg per day. Hyperlipidemia needed specific medications with statins and fenofibrate. Currently, at the age of 69, he has moderate high blood pressure

values controlled under daily 80 mg of telmisartan.

Case report 2

This is a 49-year-old female with irrelevant family history who became hypertensive since the age of 37 (maximum systolic values of 200 mmHg). At age of 42 years, while she was investigated for performing a cholecystectomy (which was soon done), a left adrenal tumour of 1.2 by 0.9 by 0.9 cm was discovered at CT scan. Only three years later she was investigated for secondary endocrine hypertension after having a short episode of mild hypopotassemia and a tumour production of aldosterone was linked with the adrenal mass (Table 3). She associated hypercholesterolemia as additional metabolic risk factor. The blood pressure was controlled with calcium and beta adrenergic blockers as well as spironolactone.

Parameter	Patient's value	Normal Limits	Units
One month before adrenalectomy			
Serum K (potassium)	3.4	3.5-5.1	mmol/L
Plasma aldosterone	172	29-161	pg/mL
Plasma Aldosterone /renin ratio	39.22	<20	
Plasma morning ACTH (Adrenocorticotrophic Hormone)	23.49	3-66	pg/mL
Plasma morning cortisol	16.17	6-21	µg/dL
Chromogranin A	75	20-125	ng/mL
Plasma metanephrines	18	10-90	pg/mL
Plasma normetanephrines	31	20-200	pg/mL
TSH (Thyroid Stimulating Hormone)	1.4	0.5-4.5	µUI/mL
Four days after left laparoscopic adrenalectomy			
Serum K (serum potassium)	3.4	3.5-5.1	mmol/L
Plasma aldosterone (orthostatic)	122.05	40-310	pg/mL
Plasma renin (orthostatic)	0.6	3.3-31.71	pg/mL
Plasma aldosterone (clinostat)	47.16	10-160	pg/mL

Plasma renin (clinostat)	<0.5	3.3-31.71	pg/mL
Three months after left laparoscopic adrenalectomy			
Serum K (potassium)	4.7	3.5-5.1	mmol/L
One year after left laparoscopic adrenalectomy			
Urinary K (potassium)	62.9	25-125	mmol/24-h
Plasma aldosterone (orthostatic)	78.81	40-310	pg/mL
Plasma renin (orthostatic)	0.5	2.64-27.66	pg/mL
Plasma aldosterone (clinostat)	76.15	10-160	pg/mL
Plasma renin (clinostat)	0.3	1.68-23.94	pg/mL
Four years after left laparoscopic adrenalectomy			
Serum K (potassium)	3.59	3.5-5.1	mmol/L
Plasma aldosterone (orthostatic)	257	24.4-403	pg/mL
Plasma aldosterone (clinostat)	178	18.8-256.7	pg/mL

Table 3 - Biochemical and hormonal profile of a 49-year-old female diagnosed and operated for a Conn's syndrome caused by a left adrenal tumour; laparoscopic adrenalectomy was performed at the age of 45

Left laparoscopic surgery was done without any complication. Four days after adrenal removal, potassium level was stationary but aldosterone decreased to normal limits (Table 3). She was discharged within 7 days. The pathological report pointed macronodular hyperplasia of left adrenal cortex involving glomerular and fascicular areas. Three months later, the potassium levels were within normal limits while the dose of hypotensive drugs decreased (Table 3). The hormonal profile assessed one year later ruled out any adrenal anomalies while the patient remained mildly hypertensive. Currently, at the age of 49, the biochemistry and endocrine panel is normal with residual high blood pressure controlled

with low doses of calcium and beta adrenergic blockers (Table 3).

Discussions

PH is one of the few treatable causes of hypertension due to adrenalectomy but it is not always easy to be recognised even its prevalence among patients with resistant high blood pressure is approximately 20%, ranging incident ages being between 20-60 years [3]. The male patient had an 18- year history of arterial hypertension and finally the clue to PH discovery was hypokalemia which may appear several years after cardiovascular anomalies [8,9]. The female case, also had 7 years between first raise of the blood pressure and adrenalectomy. She came for endocrine check-up only after a small decrease of potassium levels was found despite the fact that she also had a 3 years history of an adrenal incidentaloma (discovered while performing abdominal ultrasound pre-cholecystectomy). But most of cases actually have normal potassium [10,11]. However, exceptional complications as tetraplegia are described due to extremely low potassium [12]. Cardio-metabolic impairment and adrenal mass are also findings on adrenal Cushing's syndrome but rarely synchronous Conn's syndrome is described [13,14]. The male subject had mild elevation of urinary free cortisol without clinical significance and normalization after adrenalectomy. The female's pathological report revealed some fascicular areas involved without a clinical or endocrine correlate. Before tumour removal, specific tests in patients with low PRA may be done like oral sodium loading, saline infusion, fludrocortisone suppression, and captopril test but both our cases were highly suggestive for PH once the suspicion was started so none of these were necessary [15]. Moreover, the man subject was treated with spironolactone to correct hypopotassemia and this impairs the interpretation of tests [4,15]. Glucose profile was improved after the excision of aldosteron producing tumour in the first case while the second had no such anomaly which is generally found in 15% of cases (potentially correlated with micro- and macro- vascular complications) [16]. Regarding the multinodular goitre in first case, association with PH

seems coincidental but a positive correlation between TSH and blood pressure has been identified in normotensives and in patients with essential hypertension [7,17]. The second case displayed an incidental adrenal tumour. Although the patient was already hypertensive the investigations were done for gallbladder problems. Screening for PH in incidentaloma is rather expensive but the clinical frame of complications, age of onset, relevant family history, etc will indicate the patients who are worth to be tested [18,19]. In young subjects with high blood pressure, PH should be taken into account as the presented second patient who became hypertensive since the age of 37 [20]. As seen in other adrenal conditions like pheochromocytoma or Cushing's syndrome, adrenalectomy cures the disease [21,22]. However, long time endothelial exposure to increased blood pressure elevates the risk of persistent postoperative hypertension; even lower doses and number of drugs are needed to control it and this aspect probably is based on a genetic background [23]. As limits of our cases series, we mention the heterogeneous assays for aldosterone to renin ratio which represents a general issue in this field [24,25].

Conclusions

Surgery for adrenals in primary hyperaldosteronism is one elegant option which may cure the condition. A high index of suspicion and a systematic approach is useful in identifying and proving the diagnosis. Association with other endocrine disorders diversify the clinical appearance. Delaying the diagnosis and adrenalectomy decreases the chance of high blood pressure remission after adrenal removal.

References

- [1]Nishimoto K, Seki T, Kurihara I, Yokota K, Omura M, Nishikawa T, Shibata H, Kosaka T, Oya M, Suematsu M, Mukai K. Case Report: Nodule Development From Subcapsular Aldosterone-Producing Cell Clusters Causes Hyperaldosteronism. *J Clin Endocrinol Metab.* 2016 Jan; 101(1):6-9.
- [2]Hanslik G, Wallaschofski H, Dietz A, Riestner A, Reincke M, Allolio B, Lang K, Quack I, Rump LC,

- Willenberg HS, Beuschlein F, Quinkler M, Hannemann A; participants of the German Conn's Registry. Increased prevalence of diabetes mellitus and the metabolic syndrome in patients with primary aldosteronism of the German Conn's Registry. *Eur J Endocrinol*. 2015 Nov; 173(5):665-75.
- [3]Hannesmann A, Wallaschofski H. Prevalence of primary aldosteronism in patient's cohorts and in population-based studies -a review of the current literature. *Horm Metab Res*. 2012; 44:157-162.
- [4]Viola A, Tizzani D, Monticone S, Crudo V, Galmozzi M, Burrello J, Versace K, Loiacono M, Veglio F, Mulatero P. Diagnosis and treatment of unilateral forms of primary aldosteronism. *Curr Hypertens Rev*. 2013; 9:156-165.
- [5]Ronconi V, Turchi F, Appolloni G, di Tizio V, Boscaro M, Giacchetti G. Aldosterone, mineralocorticoid receptor and the metabolic syndrome: role of the mineralocorticoid receptor antagonists. *Curr Vasc Pharmacol*. 2012;10:238-246.
- [6]Armanini D, Nacamulli D, Scaroni C, Lumachi F, Selice R, Fiore C, Favia G, Mantero F. High prevalence of thyroid ultrasonographic abnormalities in primary aldosteronism. *Endocrine*. 2003 Nov; 22(2):155-60.
- [7]Turchi F, Ronconi V, di Tizio V, Boscaro M, Giacchetti G. Blood pressure, thyroid-stimulating hormone, and thyroid disease prevalence in primary aldosteronism and essential hypertension. *Am J Hypertens*. 2011 Dec; 24(12):1274-9.
- [8]Vutthikraivit W, Assanatham M, Sriphrapradang C. Hypokalemic Hypertension Leading to a Diagnosis of Autosomal Dominant Polycystic Kidney Disease. *Electrolyte Blood Press*. 2016 Jun; 14(1):11-5.
- [9]Vakkalanka S, Zhao A, Samannodi M. Primary hyperaldosteronism: a case of unilateral adrenal hyperplasia with contralateral incidentaloma. *BMJ Case Rep*. 2016 Jul; 14:2016.
- [10]Moradi S, Shafiepour M, Amirbaigloo A. A Woman with Normotensive Primary Hyperaldosteronism. *Acta Med Iran*. 2016 Feb; 54(2):156-8.
- [11]Rodríguez Maya B, Rodríguez Goncer I, Diego Hernández C. Hypokalemia, a key clinical data for diagnosing primary hyperaldosteronism. *Hipertens Riesgo Vasc*. 2016 Apr-Jun; 33(2):69-73.
- [12]Poiana C, Carsote M, Chirita C, Vasilescu F, Terzea D, Hortopan D, Petrescu R, Coculescu M. Hypokalemic tetraplegia caused by aldosteron secreting adrenal tumor-from particular to general. *Romanian Journal of Endocrinology and Metabolism*. 2008;7(3):95-107.
- [13]Hiraishi K, Yoshimoto T, Tsuchiya K, Minami I, Doi M, Izumiyama H, Sasano H, Hirata Y. Clinicopathological features of primary aldosteronism associated with subclinical Cushing's syndrome. *Endocr J*. 2011; 58(7):543-51.
- [14]Lee SE, Kim JH, Lee YB, Seok H, Shin IS, Eun YH, Kim JH, Oh YLssss. Bilateral Adrenocortical Masses Producing Aldosterone and Cortisol Independently. *Endocrinol Metab (Seoul)*. 2015 Dec; 30(4):607-13.
- [15]Sabbadin C, Fallo F. Hyperaldosteronism: Screening and Diagnostic Tests. *High Blood Press Cardiovasc Prev*. 2016 Jun; 23(2):69-72.
- [16]Zavatta G, Casadio E, Rinaldi E, Pagotto U, Pasquali R, Vicennati V. Aldosterone and type 2 diabetes mellitus. *Horm Mol Biol Clin Investig*. 2016 Apr 1; 26(1):53-9.
- [17]Krysiak R, Okopien B. Coexistence of primary aldosteronism and Hashimoto's thyroiditis. *Rheumatol Int*. 2012 Aug; 32(8):2561-3.
- [18]Monticone S, Viola A, Tizzani D, Crudo V, Burrello J, Galmozzi M, Veglio F, Mulatero P. Primary aldosteronism: who should be screened? *Horm Metab Res*. 2012 Mar; 44(3):163-9.
- [19]Arnaldi G, Boscaro M. Adrenal incidentaloma. *Best Pract Res Clin Endocrinol Metab*. 2012 Aug; 26(4):405-19.
- [20]Trifanescu R, Carsote M, Carageorgheopol A, Hortopan D, Dumitrascu A, Dobrescu M, Poiana C. Screening for Secondary Endocrine Hypertension in Young Patients, *Maedica-a Journal of Clinical Medicine*. 2013; 8(2):108-115.
- [21]Albu SE, Carsote M, Capatina C, Dumitrascu A, Ghemigian A. Adrenal surgical approach in a women with synchronous bilateral adrenal tumours. *Journal of Surgical Sciences*. 2015; 2(3):132-135.
- [22]Baloescu R, Carsote M, Albu SE, Valea A. Multiple surgeries and long-term endocrine follow-up in a MEN 2A syndrome. *Journal of Surgical Sciences*. 2015;2(4):204-209.
- [23]Xie LF, Ouyang JZ, Wang AP, Wang WB, Li XT, Wang BJ, Mu YM. Gene Expression Profile of Persistent Postoperative Hypertension Patients with Aldosterone-producing Adenomas. *Chin Med J (Engl)*. 2015 Jun 20; 128(12):1618-26.
- [24]Seiler L, Rump LC, Schulte-Mönting J, Slawik M, Borm K, Pavenstädt H, Beuschlein F, Reincke M. Diagnosis of primary aldosteronism: value of different screening parameters and influence of antihypertensive medication. *Eur J Endocrinol*. 2004 Mar; 150(3):329-37.
- [25]Niizuma S, Nakahama H, Kamide K, Fukuchi K, Iwanaga Y, Nakata H, Yoshihara F, Horio T, Nakamura S, Kawano Y. The cutoff value of aldosterone-to-renin ratio for the diagnosis of primary aldosteronism in patients taking antihypertensive medicine. *Clin Exp Hypertens*. 2008 Oct;30(7):640-7.